

Title :

Rare case of intra-oral palatal (soft palate) fibro-lipoma

Running title:

Soft palate fibro-lipoma

Authors:

1. Corresponding author: * Manit M. Mandal, Senior Resident (SR)

2. Ajay J. Panchal, Professor & Head

3. Rakesh Kumar, Associate Professor

4. Parth B. Kapadia, Assistant Professor

5. Neel Parmar, Resident

Affiliation:

Department of Otorhinolaryngology, Surat Municipal Institute of Medical Education and Research, Sahara Darwaja, Surat (395001), Gujarat, India

***Correspondence:**

Dr. Manit M. Mandal,

E-mail: drmanit28@gmail.com

Phone number: +91 9924115951, +91 6355799127

Dept. of Otorhinolaryngology, Surat Municipal Institute of Medical Education and Research, Sahara Darwaja, Surat (395001), Gujarat, India

Financial disclosure:

Funding: No funding sources

Conflict of interest:

None declared

Ethical approval:

The study was approved by the Institutional Ethics Committee of SMIMER, Surat, Gujarat (India)

Abstract

Background: Case study of 30 years old male patient having smooth surfaced, firm, non-pulsatile mass found situated over upper surface of soft palate in immediate posterior close relationship with the posterior-most part of the nasal septum leading to a suspended mass hanging in the nasopharynx with support of a small stalk.

Methods: After complete evaluation, patient underwent combined approach (Trans-oral + Endoscopic) excision of the mass under general anaesthesia with coblation of the stalk behind the nasal septum.

Results: Histopathological examination of the mass suggested presence of abundant adipose tissue, with trace presence of fibro-collagenous tissue and chronic inflammatory cells, with no evidence of any malignancy. Possibility of intra-oral lipoma most likely.

Conclusion: Lipoma should be considered while evaluating a palatal mass. Surgical excision is the treatment of choice and careful radiological examination pre-operatively is recommended.

INTRODUCTION

The palate forms a division between nasal and oral cavity. It is divided into two parts hard palate and soft palate.

A mass or growth in the palate can result from a range of pathologies which includes periapical lesion, periodontal diseases, reactive process, salivary gland pathologies or neoplastic process.

They may be congenital or acquired. Mass of congenital origin are usually associated with unerupted teeth and torus palatinus while acquired condition resulting from dental abscess, salivary gland neoplasm, fibro-osseous lesion, fibrous or fatty lump, neurogenic tumors, epithelial or connective tissue neoplasm such as papilloma, squamous cell carcinoma, brown tumor.

They are best examined by inspection and palpation and with the help of radiology we can rule out pathologies but confirmatory diagnosis can be reached only with help of histopathology.

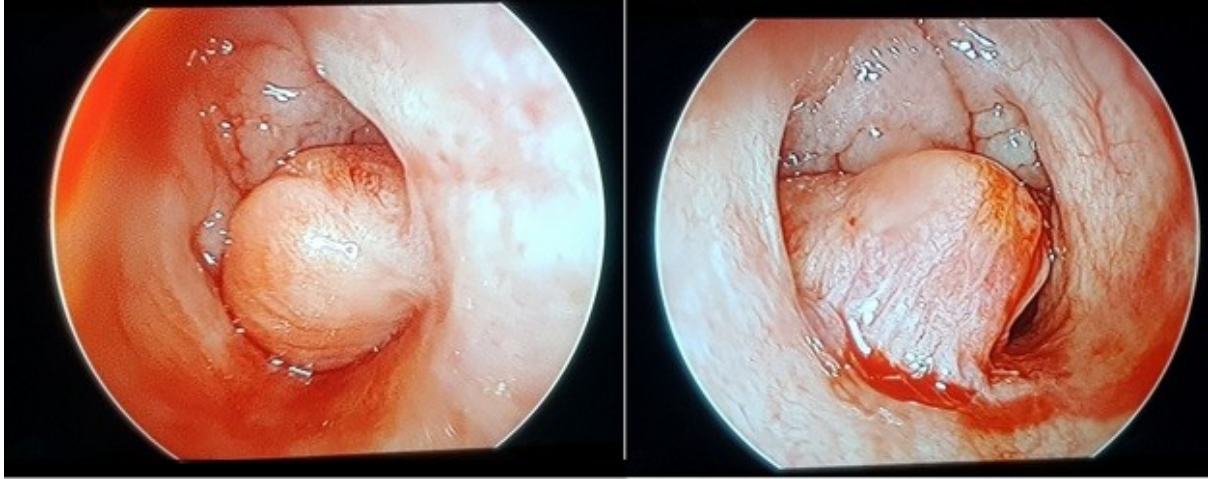Lipoma is a benign mesenchymal neoplasm composed of mature adipocytes, usually surrounded by a thin fibrous capsule.^[1] They are the most common soft tissue tumor in the human body and about 20% of cases occur in the head and neck region.^[1] Oral lipomas are however rare and comprise only 0.5–4% of all benign tumors of the oral cavity.^[1,2]

They usually present as painless, well-circumscribed, slow-growing submucosal or superficial lesions. The most frequent site is buccal mucosa, followed by tongue, floor of mouth, lips, and gingiva.^[1,2] Here, we report a case of 30 years male patient with mass on soft palate and discuss its clinical relevance.

CASE REPORT

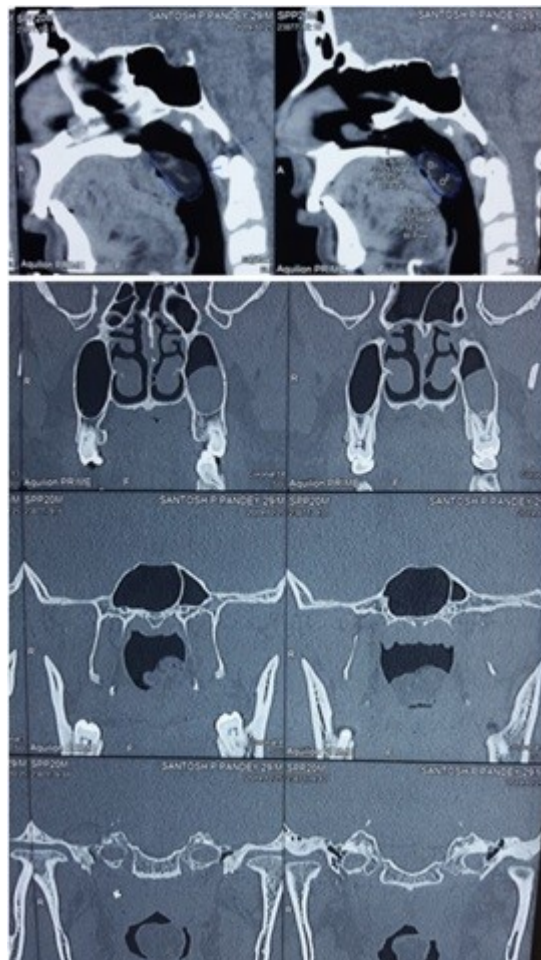
A case of 30 years old male patient presented with chief complaints of post nasal drip, nasal obstruction (right side > left side), headache (intermittent) since 3 years. There was also history of snoring and mouth breathing during sleep. There weren't any complaints pertaining to speech or deglutition.

On diagnostic nasal endoscopy there was slight deviated nasal septum towards left side anteriorly and a smooth surfaced, firm, non-pulsatile mass found situated over upper surface of soft palate in immediate posterior close relationship with the posterior-most part of the nasal septum leading to a suspended mass hanging in the nasopharynx with support of a small stalk. (Fig. 1)



(Fig. 1: Diagnostic endoscopic examination showing the mass)

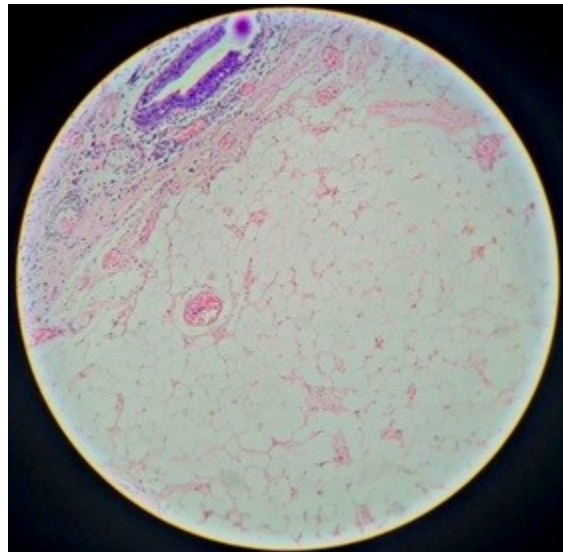
Patient was advised Computed Tomography paranasal sinus (CT PNS) which showed presence of fairly large lobulated (3x2x2 cm) predominantly fat density lesion situated over the soft palate and projecting into the nasopharynx causing significant nasopharyngeal obstruction. (Fig. 2)



(Fig 2: CT PNS showing fat density lesion present over soft palate extending to nasopharynx)

Patient underwent combined approach (Trans-oral + Endoscopic) excision of the mass under general anaesthesia with coblation of the stalk behind the nasal septum. Mass was sent for histopathological examination. Patient's surgery and post-surgical stay of 2 days were uneventful with no residual masticatory or speech disturbances. He was started on oral diet on the 3rd postoperative day and remained comfortable and asymptomatic even on follow up.

Histopathological examination of the mass suggested presence of abundant adipose tissue, with trace presence of fibro-collagenous tissue and chronic inflammatory cells, with no evidence of any malignancy. (Fig. 3)



(Fig. 3: Histopathological examination findings)

DISCUSSION

Lipoma is a benign slow-growing neoplasm composed of mature fat cells. The first description of oral lipomas was given by Roux ^[3] in 1848 in a review of alveolar mass; he referred it as a “yellow epulis.” Lipomas are rare in the oral cavity. The most common location of lipoma in the oral cavity is the buccal mucosa, a region abundant in fatty tissue, followed by tongue, lips, and floor of the mouth ^[1,2] This pattern of location of the tumor corresponds to the quantity of fat deposits in the oral cavity. The palate has very little fatty tissue and the incidence of a lesion here is quite low. ^[4] Although lipoma may resemble fat cells histologically, they differ from them metabolically. It has been shown that the fat of lipoma is not used for energy production during the starvation period, as it happens with normal adipose tissue. ^[1,2]

No clear explanation exists regarding the pathogenesis of oral lipomas ^[4]. Various mechanisms have been proposed for explaining the origin of these tumors in the oral cavity, this range from origin from lipoblastic embryonic cell nests, metaplasia of muscle cells, and trauma to chronic irritation and fatty degeneration. ^[5,6]

Although most lipomas are asymptomatic, but if symptomatic, the symptoms depend upon the rate of growth, size, and location of the tumor. Commonest presentation is of a painless palpable mass where examination reveals a well-defined, soft to firm, and smooth-surfaced

tumor. The tumor is soft and flat when the underlying muscle is relaxed and becomes firm and more spherical when the muscle contracts.

The differential diagnosis includes lesions with similar clinical features, such as thyroglossal duct cysts, pleomorphic adenoma, mucoepidermoid carcinoma, lymphoepithelial, or dermoidal cysts.^[1]

There are various subtypes of intra-oral lipomas namely simple lipoma, fibrolipomas, angiolipomas, intramuscular or infiltrating lipomas, pleomorphic lipomas, spindle-cell lipomas, salivary gland lipomas (sialolipomas), and myxoid lipomas.^[1,2,4,5] Amongst these, simple lipoma are the most common form seen.

The diagnosis is based on the cytological examination of the tissue. Fine needle aspiration cytology (FNAC) is always a good option, but histopathological examination of tissue is definitive and hence confirmatory. Radiological evaluation with CT scan is seldom necessary which helps in knowing the nature as well as the extent of the mass including infiltration into underlying structures.

Treatment is indicated in symptomatic patients especially if disturbs daily pursuits which may or may not include interference with speech, mastication, or if cosmetically unacceptable.^[4-6]

The treatment of oral lipomas regardless of the histologic variance is surgical excision.^[4-6] The prognosis is good as recurrences are uncommon, but they may occur in the infiltrative variant.

CONCLUSION

To conclude, lipomas are uncommon tumors in the oral cavity and palate being the rarest amongst them as is our case. It would be strongly advocated to keep lipoma in the differential diagnosis when evaluating a palatal mass. Also it is worth mentioning and recommending that a careful radiological examination of large lesions arising from the palate is a must before approaching for surgery.

Financial support and sponsorship

Nil.

Conflicts of interest

There are no conflicts of interest.

References:

1. Fregnani ER, Pires FR, Falzoni R, Lopes MA, Vargas PA. Lipomas of the oral cavity: Clinical findings, histological classification and proliferative activity of 46 cases. *Int J Oral Maxillofac Surg* 2003;32:49-53.
2. Furlong MA, Fanburg-Smith JC, Childers EL. Lipoma of the oral and maxillofacial region: Site and subclassification of 125 cases. *Oral Surg Oral Med Oral Pathol Oral Radiol Endod* 2004;98:441-50.
3. Roux M. On exostosis: Their character. *Am J Dent Sci* 1848;9:133-4.
4. Manor E, Sion-Vardy N, Joshua BZ, Bodner L. Oral lipoma: Analysis of 58 new cases and review of the literature. *Ann Diagn Pathol* 2011;15:257-61.
5. Naruse T, Yanamoto S, Yamada S, Rokutanda S, Kawakita A, Takahashi H, *et al.* Lipomas of the oral cavity: Clinicopathological and immunohistochemical study of 24 cases and review of the literature. *Indian J Otolaryngol Head Neck Surg* 2015;67 Suppl 1:67-73.
6. Navaneetham A, Rao A, Gandhi A, Jeevan CA. Lipoma involving the masticator space. *Ann Maxillofac Surg* 2011;1:93-4.