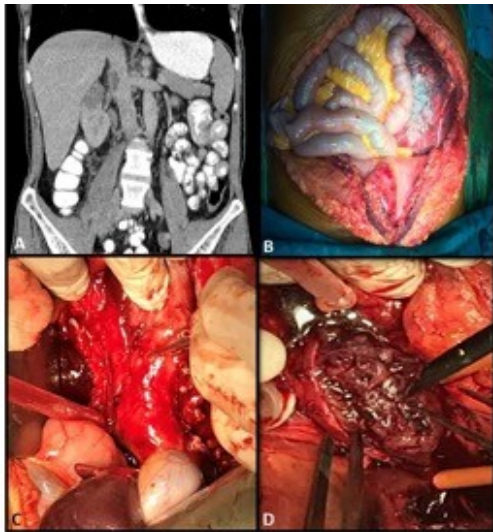


Figure Legends:

Figure 1- Figure 1- Radiologic and perioperative images of the patients with venous thrombosis.



- (a)** Preoperative CT-scan of a 56-year-old male with a right Level II tumor thrombus. This patient lived 15 months after surgery without evidence of disease;
- (b)** Combined surgical incision of a 38-year-old male with an advanced left renal mass and Level IV tumor thrombus; **(c,d)** Vena cava dissection and longitudinal cavotomy.

Figure 2- Kaplan-Meier curves showing overall and disease-free survival based on (a) metastasis, (b) tumor size and (c) thrombus level.

Figure 2a- Kaplan-Meier curves showing overall and disease-free survival in clinical M0 and M1 patients.

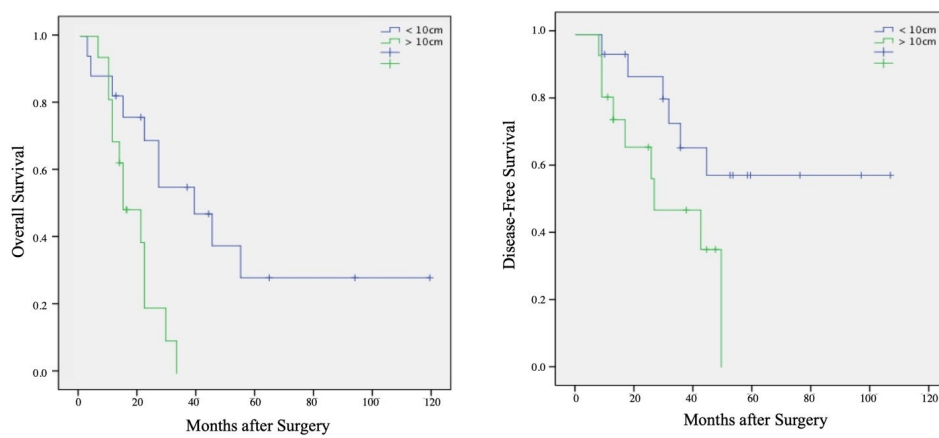


Figure 2b- Kaplan-Meier curves showing overall and disease-free survival based on tumor size.

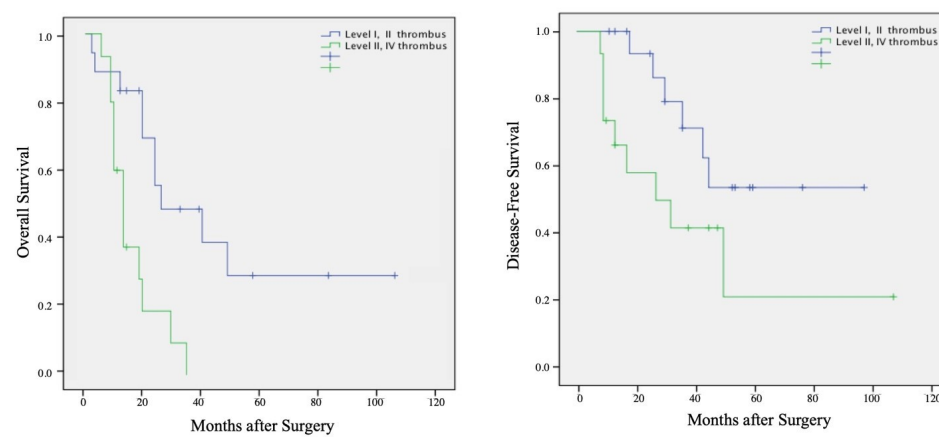


Figure 2c- Kaplan- Meier curves showing overall and disease-free survival for different levels of venous thrombus.

