

# Case Report: Adult Presentation of Acute Epiglottitis with Severe Airway Complications – Emergency Management and Surgical Intervention

Ahmed Sajid<sup>1</sup>, Muhammad Hamza Rafique <sup>1</sup>, and Farva Khan<sup>1</sup>

<sup>1</sup>Affiliation not available

February 23, 2024

## Introduction

Epiglottitis refers to inflammation of the epiglottis and adjacent supraglottic structures, primarily due to infection [1]. Without treatment, epiglottitis can progress to life-threatening airway obstruction. Historically associated with pediatric populations, particularly causing emergency airway obstruction in young children under the age of 6, the epidemiology of epiglottitis has shifted with the widespread use of conjugate vaccines. In recent years, cases in adults have become increasingly rare, making the presentation of epiglottitis in the adult population an intriguing and uncommon occurrence.

## Pathophysiology and Airway Obstruction in Children:

The pathophysiology of epiglottitis involves inflammation of the epiglottis and adjacent structures, often resulting from bacteremia or invasion of epithelial layer by pathogenic agent [2,3,4]. In children, this inflammation can lead to acute upper airway obstruction. The proximity of the inflamed epiglottis to the airway makes it particularly susceptible to swelling, potentially causing respiratory distress [3,4]. This life-threatening complication emphasizes the urgency of prompt diagnosis and intervention in pediatric cases. Understanding the pathophysiological mechanisms is crucial for effective management and prevention of severe outcomes.

## Unique Presentation in Adults – Our Case:

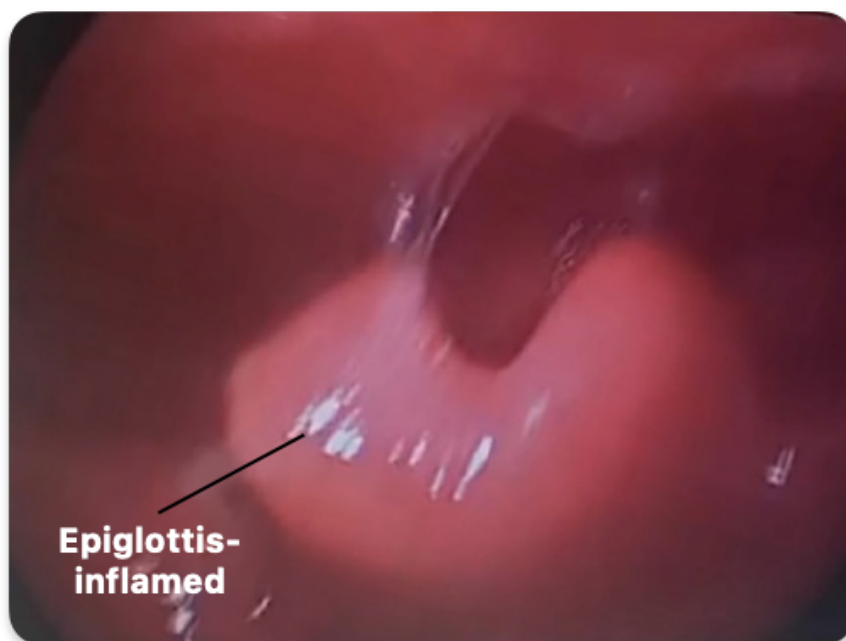The epidemiological landscape of acute epiglottitis has evolved significantly since the introduction of vaccines against *H. influenzae* type b (Hib), but may still be isolated in completely vaccinated children [5,6,7,8,9]. In the current post-conjugate vaccine era, epiglottitis has predominantly shifted towards affecting adults, with an estimated annual incidence ranging from 0.6 to 1.9 cases per 100,000 [10,11] and an overall mean age of onset between 45 to 49 years [12,13]. Notably, our case report adds a unique dimension to this evolving scenario. The 28-year-old male patient sought emergency medical attention when he presented with severe respiratory difficulty, with a history of sore throat and vomiting over three days, eventually leading to the diagnosis of acute epiglottitis [14]. In contrast to the typical course observed in adults, our case introduces an uncommon complication – acute upper airway obstruction. This deviation challenges the established norms and highlights the dynamic nature of epiglottitis in adult's post-vaccination. The patient's presentation highlights the importance of vigilance in recognizing and managing uncommon complications associated with this condition in the adult population. Additionally, comorbid conditions such as hypertension, diabetes mellitus, and other factors mentioned in the epidemiological context contribute to noninfective causes of acute epiglottitis and its management in adults [15,16,17,18].

## Case Presentation:

### Hospital Course:

The 28-year-old male patient presented to the outpatient department with a 3-day history of sore throat, vomiting, and fever. Upon arrival at 12:50 pm, he exhibited severe respiratory difficulty and stridor. Clinical examination revealed a severely congested throat with bilateral grade 2 tonsillar hypertrophy and follicles. Due to the emergent nature of the situation, an emergency tracheostomy was performed. Prior to the tracheostomy, the patient received immediate medical management, including intravenous administration of Ceftriaxone 1g BD, Metronidazole 500mg TDS, Dexamethasone 4mg OD, Omeprazole 40 mg OD, and Paracetamol 1g TDS.

Under aseptic measures, the patient was taken to the operating room. A tracheostomy was performed under local anesthesia- confirmed by an anesthesiologist. General anesthesia was administered, and a rigid direct laryngoscope was passed which revealed a swollen epiglottis(**Figure 1A**) . True and false vocal cords, bilateral arytenoids, and aryepiglottic folds were normal, and the subglottic region appeared normal. Bilateral pyriform was not visible due to swelling. The patient was handed over to the anesthesia department with oxygen saturation at 99%.



(**Figure 1A** - Image captured through video-laryngoscope post-tracheostomy)

Per-operative findings during emergency tracheostomy followed by direct laryngoscopy revealed a significantly enlarged epiglottis(**Figure 1A**) , providing insight into the cause of the severe congestion observed during clinical examination. Hypertrophy of the epiglottis confirmed the diagnosis of acute epiglottitis.

Laboratory investigations were undertaken to elucidate the diagnosis and to understand the extent of the infection. A complete blood count (CBC) was performed, and the results are depicted in **Table 1** . The CBC revealed an elevated Total Leukocyte Count (TLC) indicating a pronounced systemic response to infection. This marked leukocytosis is often associated with bacterial infections and was suggestive of a severe infectious process, corroborating the clinical suspicion of acute epiglottitis. Further differentiation of the leukocyte profile, as detailed in Table 2, showed a disproportionately high neutrophil percentage of 92%. This neutrophilia is a hallmark of an acute bacterial infection, providing further evidence to support the infectious etiology of the patient's epiglottitis. The differential count, in conjunction with the elevated TLC,

Highlights the body’s robust immunological response to the pathogenic insult.

These finding, combined with the comprehensive medical regimen administered pre-tracheostomy contributed to the successful emergency management of the patient’s condition.

The patient was admitted to for close medical surveillance and management. Serial laboratory investigations were integral to monitoring the patient’s progress. **Tables 1 and 2** illustrate the trajectory of the Total Leukocyte Count (TLC) and the differential leukocyte percentages across multiple time points.

A consistent decline in TLC was observed, indicating a favorable response to the instituted medical regimen. Concurrently, there was a noted decrease in neutrophil percentage, which further suggested a resolution of the acute inflammatory state. These laboratory trends were not only prognostic but also guided the clinical decisions regarding the intensity of medical therapy and infection control measures.

The patient’s clinical course, characterized by stabilization in vital signs and symptomatic relief, mirrored the improvements seen in the laboratory parameters. This congruence was indicative of a successful post-operative recovery and an effective response to the medical treatment.

**Investigations:**

**Blood complete Picture:**

**Blood Complete Picture**

Reference range DOA	TLC (10 <sup>6</sup> /l)	RBC ml/	Hb (g/dl)	HCT (%)	Πλατελετ ζουντ/μΛ
	4000-10000	4.5-5.5	13-17	46-50	200000-550000
1 <sup>st</sup>	24940	5.92	11.1	33.6	234000
2 <sup>nd</sup>	10960	4.6	12.7	38.2	349000
6 <sup>th</sup>	17670	6.6	12.3	36.4	453000
9 <sup>th</sup>	13760	6.46	11.8	36.1	427000

(Table 1)

**Differential TLC count:**

**Differential TLC count**

Date	TLC (10 <sup>9</sup> /l) Ref range: 4000-10000	Neutrophils (%) Ref range: 45-70	Lymphocytes (%) Ref range: 20-40
1 <sup>st</sup>	24940	92.2	0.8
2 <sup>nd</sup>	10960	84.3	9.6
6 <sup>th</sup>	17670	77.7	17.5
9 <sup>th</sup>	13760	74.5	18

(Table 2)

**Condition on Discharge:**

The patient was stable clinically and vitally, with successful decannulation and dressing. No hoarseness or breathing difficulty was observed.

**Medication advised on discharge:**

1. Tab Cefixime 400mg (1+0+0) per oral for 7 days
2. Tab Ibuprofen 400mg (1+1+1) per oral for 5 days

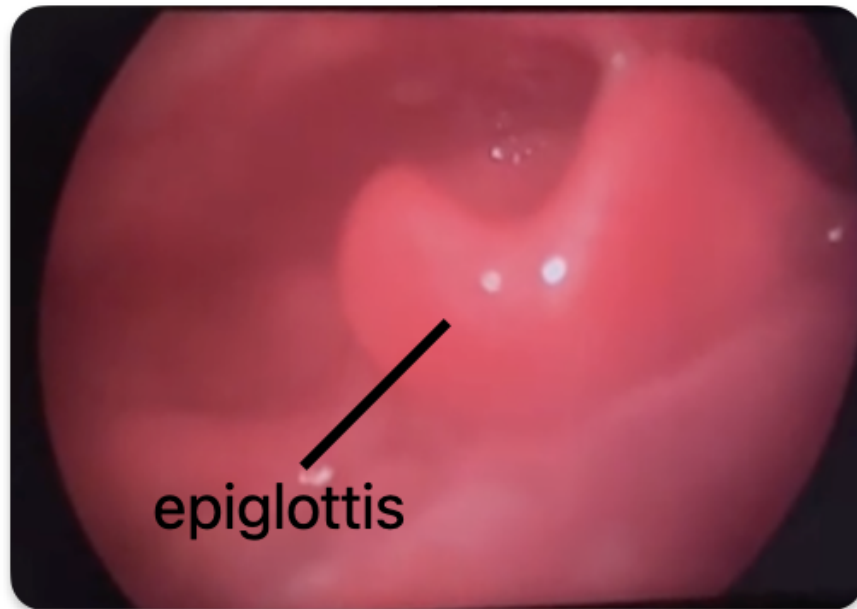
3. Cap Omeprazole 40mg (1+0+0) per oral for 10 days

### Patient follow up in OPD 10 days after being discharged

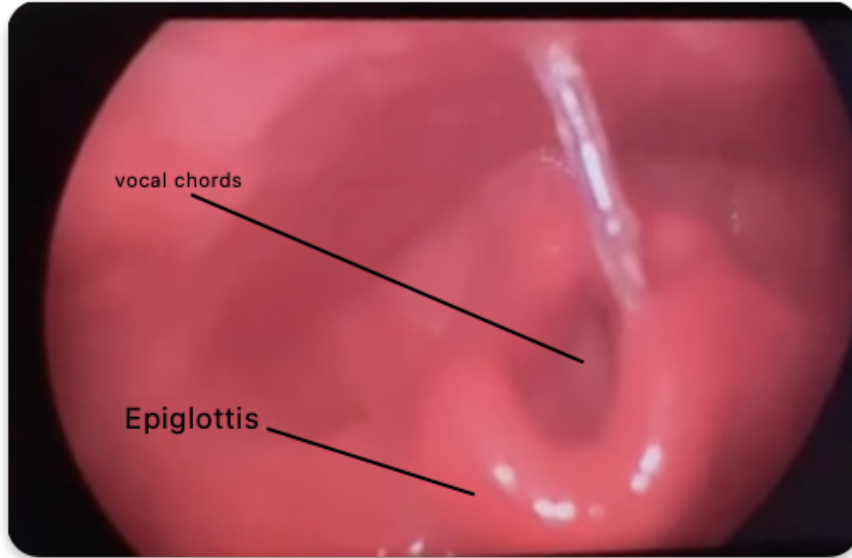
During a follow-up visit at the outpatient department, the patient underwent a thorough physical examination, was unremarkable. The patient appeared alert, was in no distress, and was otherwise in a good state of health. To assess the condition of the epiglottis and the surrounding airway structures, video laryngoscopy was performed. The procedure aimed to evaluate the presence of residual inflammation and to ensure the trachea remained unobstructed.

The findings from the video laryngoscopy were encouraging. There was a marked reduction in the epiglottic inflammation (as demonstrated in **Figure 2A**), and the vocal cords were clearly visualized without any signs of swelling or obstruction (**Figure 2B**). Additionally, the examination confirmed that the trachea was open and fully patent, with the surrounding anatomical structures being normal in appearance (**Figure 2C**). These observations were indicative of a positive response to treatment and a significant recovery from the initial presentation.

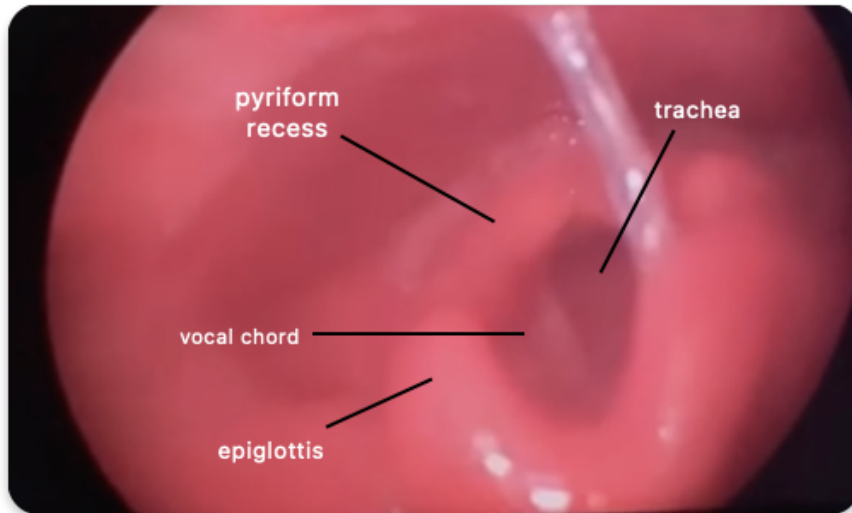
### Direct visualization through VDL:



(Figure 2A- Image captured through video-laryngoscope on follow-up)



(Figure 2B- Image captured through video-laryngoscope on follow-up)



(Figure 2C- Image captured through video-laryngoscope on follow-up)

#### Discussion :

**Acute Epiglottitis in Adults:** The presented case highlights an uncommon complication of acute epiglottitis, traditionally associated with pediatric populations [19]. The post-conjugate vaccine era has seen a shift in its epidemiology, with adults now occasionally presenting with this once predominantly pediatric condition [12,13]. While the incidence in adults has increased, the complications, particularly acute upper airway obstruction, remain exceedingly rare. This case challenges the prevailing understanding, emphasizing the importance of vigilance in recognizing atypical presentations [20,21].

**Clinical Presentation and Diagnosis:** The patient's initial symptoms of sore throat, vomiting, and fever are consistent with the prodromal phase of acute epiglottitis [14]. However, the unique aspect of this case

lies in the rapid progression to acute upper airway obstruction in an adult patient. Clinical examination revealed bilateral tonsillar hypertrophy and stridor [20,21], indicative of the severity of the condition. The decision for emergency tracheostomy was imperative to ensure a patent airway and avert a life-threatening crisis.

**Surgical Intervention and Intraoperative Findings :** The emergency tracheostomy, performed under local anesthesia, played a crucial role in securing the airway promptly. Intraoperatively, significant swelling of the epiglottis was observed [3,22]. Notably, bilateral arytenoids, and aryepiglottic folds the true and false vocal cords appeared normal, highlighting the localized nature of the inflammatory process. The absence of visible pyriformis due to swelling further contributed to the understanding of the extent of tissue inflammation.

**Laboratory and Radiological Findings:** Laboratory investigations, indicated an elevated platelet count and inflammatory markers, reflecting the acute nature of the condition. Radiological assessments, such as imaging of the neck or direct visualization through fiberoptic laryngoscopy [2,23], provided additional insights into the extent of inflammation and supported the diagnosis as explicitly mentioned in the case.

**Treatment and Outcome:** The patient responded well to the instituted treatment regimen, including antibiotic therapy and anti-inflammatory medications [24,25]. Absence of breathing difficulties at discharge signify the effectiveness of the interventions. The postoperative course was uneventful, highlighting the importance of early recognition, prompt intervention, and appropriate postoperative care.

### **Conclusion and Implications :**

This case contributes to the limited literature on acute epiglottitis in adults, emphasizing the need for heightened awareness among healthcare providers. The rarity of complications in adults necessitates a thorough understanding of atypical presentations to ensure timely and effective management. Furthermore, the case highlights the importance of considering acute epiglottitis in the differential diagnosis of respiratory distress in adults, especially in the absence of typical pediatric risk factors. Continued surveillance and reporting of such cases will further refine our understanding of this evolving clinical entity.

### **Declarations:**

#### **Ethics approval and consent to participate**

This case report adheres to ethical principles governing medical research and patient confidentiality. Informed consent was obtained from the patient for the publication of this case report, including the use of clinical data, images, and relevant medical history. All patient identifiers have been removed or anonymized to protect confidentiality. The report was conducted with integrity, honesty, and respect for the patient's autonomy, dignity, and privacy. It aligns with the principles outlined in the Declaration of Helsinki and other relevant ethical guidelines. The authors declare no conflicts of interest or financial disclosures related to this case report.

#### **Consent for publication**

Written informed consent was taken from the patient's legal guardians based on the journal's policy. Consent for publication is also provided by the patient's legal guardians abiding to the policy of the journal.

#### **Availability of data and material**

All data about this case is made available within the manuscript. Any further data or information will be made available upon request.

#### **Competing interests**

The author(s) have no conflict of interest to declare

#### **Funding**

The project is not funded by any grant or organization.

### Authors' contributions

AS, MHR and FZK contributed to conceptualization, data curation, investigation, supervision, project administration, writing-original draft, and writing review & editing. AZ<sup>4</sup>, AZ<sup>5</sup>, ZZK, AK contributed to conceptualization, writing-original draft, and writing review & editing.

### Acknowledgements

We would like to acknowledge the team of clinicians who managed this case.

### Abbreviations:

1. CBC - Complete Blood Count
2. TLC - Total Leukocyte Count
3. BD - Twice a Day (from the Latin "bis in die")
4. TDS - Three Times a Day (from the Latin "ter in die")
5. OD - Once a Day (from the Latin "omne in die")
6. DOA - Date of Admission
7. RBC - Red Blood Cell
8. Hb - Hemoglobin
9. HCT - Hematocrit
10. Hib - Haemophilus influenzae type b
11. OPD - Outpatient Department
12. VDL - Video-Direct Laryngoscopy

### References:

1. Klein MR. Infections of the Oropharynx. *Emerg Med Clin North Am.* 2019 Feb;**37**(1):69-80. doi: 10.1016/j.emc.2018.09.002. PMID: 30454781.
2. Tovar Padua, LJ and Cherry JD. Croup (laryngitis, laryngotracheitis, spasmodic croup, laryngotracheobronchitis, bacterial tracheitis, and laryngotracheobronchopneumonitis) and epiglottitis (supraglottitis). In: Feigin and Cherry's Textbook of Pediatric Infectious Diseases, 8th edition, Cherry JD, Harrison GJ, Kaplan SL, Steinbach WJ, Hotez PJ (Eds), Elsevier, Philadelphia 2019. Vol 1, p.175.
3. Glomb NWS and Cruz AT. Infectious disease emergencies. In: Fleisher and Ludwig's Textbook of Pediatric Emergency Medicine, 7th ed, Shaw KN, Bachur RG (Eds), Wolters Kluwer, Philadelphia 2016.
4. Sato S, Kuratomi Y, Inokuchi A. Pathological characteristics of the epiglottis relevant to acute epiglottitis. *Auris Nasus Larynx.* 2012 Oct;**39**(5):507-11. doi: 10.1016/j.anl.2011.10.015. Epub 2011 Nov 22. PMID: 22113103.
5. Morton E, Prahlow JA. Death related to epiglottitis. *Forensic Sci Med Pathol.* 2020 Mar;**16**(1):177-179. doi: 10.1007/s12024-019-00142-1. Epub 2019 Jul 29. PMID: 31359308.
6. Shah RK, Roberson DW, Jones DT. Epiglottitis in the Hemophilus influenzae type B vaccine era: changing trends. *Laryngoscope.* 2004 Mar;**114**(3):557-60. doi: 10.1097/00005537-200403000-00031. PMID: 15091234.
7. Tanner K, Fitzsimmons G, Carrol ED, Flood TJ, Clark JE. Haemophilus influenzae type b epiglottitis as a cause of acute upper airways obstruction in children. *BMJ.* 2002 Nov 9;**325**(7372):1099-100. doi: 10.1136/bmj.325.7372.1099. PMID: 12424174; PMCID: PMC1124584.
8. González Valdepeña H, Wald ER, Rose E, Ungkanont K, Casselbrant ML. Epiglottitis and Haemophilus influenzae immunization: the Pittsburgh experience—a five-year review. *Pediatrics.* 1995 Sep;**96**(3 Pt 1):424-7. PMID: 7651772.

9. Solomon P, Weisbrod M, Irish JC, Gullane PJ. Adult epiglottitis: the Toronto Hospital experience. *J Otolaryngol*. 1998 Dec;27(6):332-6. PMID: 9857318.
10. Briem B, Thorvardsson O, Petersen H. Acute epiglottitis in Iceland 1983-2005. *Auris Nasus Larynx*. 2009 Feb;36(1):46-52. doi: 10.1016/j.anl.2008.03.012. Epub 2008 May 23. PMID: 18502071.
11. Guldred LA, Lyhne D, Becker BC. Acute epiglottitis: epidemiology, clinical presentation, management and outcome. *J Laryngol Otol*. 2008 Aug;122(8):818-23. doi: 10.1017/S0022215107000473. Epub 2007 Sep 25. PMID: 17892608.
12. Hanna J, Brauer PR, Berson E, Mehra S. Adult epiglottitis: Trends and predictors of mortality in over 30 thousand cases from 2007 to 2014. *Laryngoscope*. 2019 May;129(5):1107-1112. doi: 10.1002/lary.27741. Epub 2018 Dec 24. PMID: 30582183.
13. Shah RK, Stocks C. Epiglottitis in the United States: national trends, variances, prognosis, and management. *Laryngoscope*. 2010 Jun;120(6):1256-62. doi: 10.1002/lary.20921. PMID: 20513048.
14. Glynn F, Fenton JE. Diagnosis and management of supraglottitis (epiglottitis). *Curr Infect Dis Rep*. 2008 May;10(3):200-4. doi: 10.1007/s11908-008-0033-8. PMID: 18510881.
15. Mayo-Smith MF, Spinale JW, Donskey CJ, Yukawa M, Li RH, Schiffman FJ. Acute epiglottitis. An 18-year experience in Rhode Island. *Chest*. 1995 Dec;108(6):1640-7. doi: 10.1378/chest.108.6.1640. PMID: 7497775.
16. Ng HL, Sin LM, Li MF, Que TL, Anandaciva S. Acute epiglottitis in adults: a retrospective review of 106 patients in Hong Kong. *Emerg Med J*. 2008 May;25(5):253-5. doi: 10.1136/emj.2007.050153. PMID: 18434453.
17. Chang YL, Lo SH, Wang PC, Shu YH. Adult acute epiglottitis: experiences in a Taiwanese setting. *Otolaryngol Head Neck Surg*. 2005 May;132(5):689-93. doi: 10.1016/j.otohns.2005.01.011. PMID: 15886619.
18. Wolf M, Strauss B, Kronenberg J, Leventon G. Conservative management of adult epiglottitis. *Laryngoscope*. 1990 Feb;100(2 Pt 1):183-5. doi: 10.1288/00005537-199002000-00014. PMID: 2299960.
19. Stroud RH, Friedman NR. An update on inflammatory disorders of the pediatric airway: epiglottitis, croup, and tracheitis. *Am J Otolaryngol*. 2001 Jul-Aug;22(4):268-75. doi: 10.1053/ajot.2001.24825. PMID: 11464324.
20. BERENBERG W, KEVY S. Acute epiglottitis in childhood; a serious emergency, readily recognized at the bedside. *N Engl J Med*. 1958 May 1;258(18):870-4. doi: 10.1056/NEJM195805012581802. PMID: 13541676.
21. Battaglia JD, Lockhart CH. Management of acute epiglottitis by nasotracheal intubation. *Am J Dis Child*. 1975 Mar;129(3):334-6. doi: 10.1001/archpedi.1975.02120400042009. PMID: 1092153.
22. Oropharyngeal examination for suspected epiglottitis. *Am J Dis Child*. 1988 Dec;142(12):1261-7. PMID: 3195518.
23. Ducic Y, Hébert PC, MacLachlan L, Neufeld K, Lamothe A. Description and evaluation of the vallecula sign: a new radiologic sign in the diagnosis of adult epiglottitis. *Ann Emerg Med*. 1997 Jul;30(1):1-6. doi: 10.1016/s0196-0644(97)70102-1. PMID: 9209217.
24. Sobol SE, Zapata S. Epiglottitis and croup. *Otolaryngol Clin North Am*. 2008 Jun;41(3):551-66, ix. doi: 10.1016/j.otc.2008.01.012. PMID: 18435998.
25. Andreassen UK, Baer S, Nielsen TG, Dahm SL, Arndal H. Acute epiglottitis—25 years experience with nasotracheal intubation, current management policy and future trends. *J Laryngol Otol*. 1992 Dec;106(12):1072-5. doi: 10.1017/s0022215100121784. PMID: 1487663.