

A rare presentation of malignant mesothelioma of the tunica vaginalis managed with immunotherapy, and a review of the literature

Kritika Mishra¹, Shihab Siddiquee², and Anna Mislant²

¹Central Adelaide Local Health Network

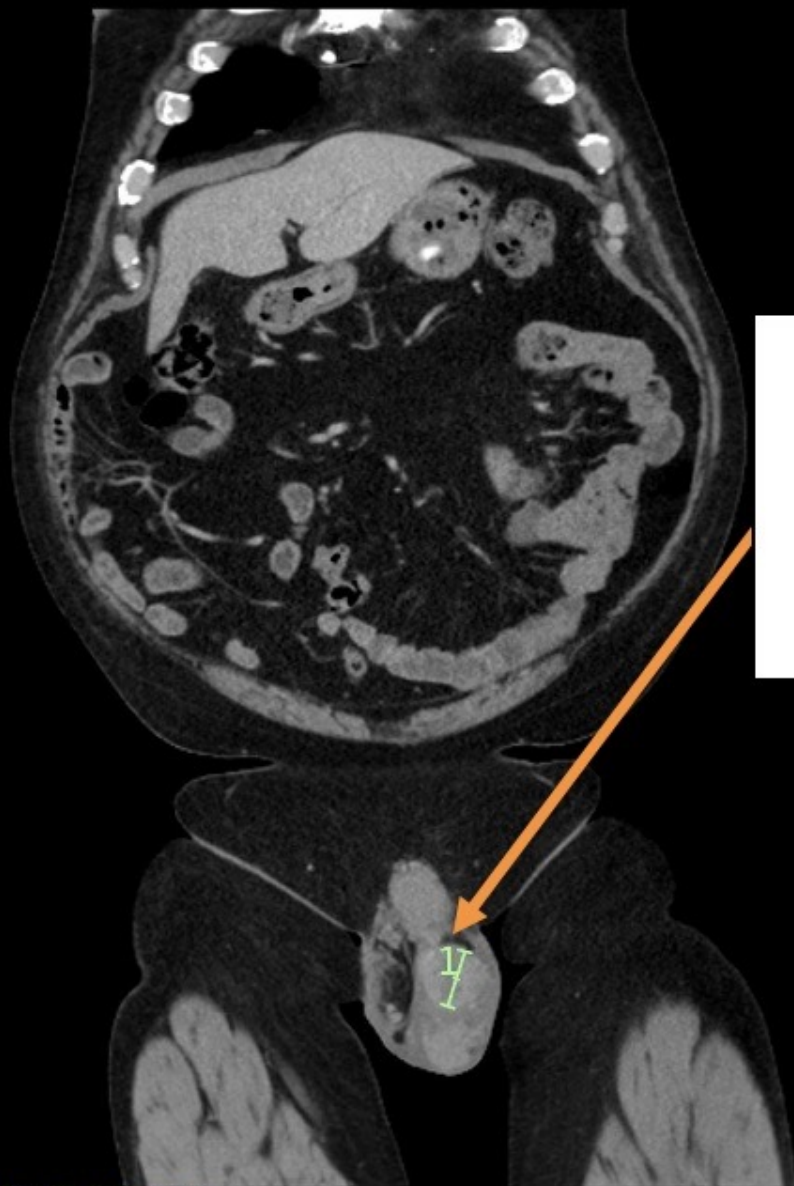
²Flinders Medical Centre

June 20, 2023

Hosted file

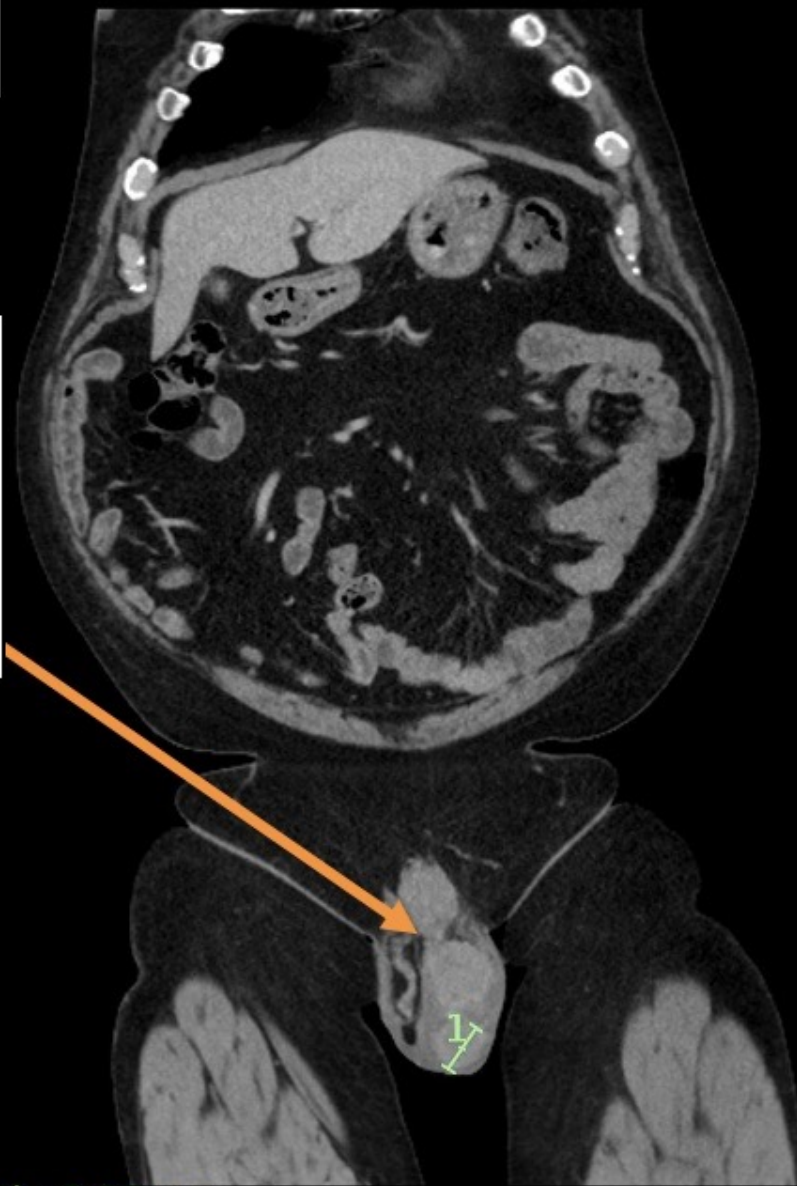
Mishra_June_2023 Authorea.docx available at <https://authorea.com/users/610501/articles/639463-a-rare-presentation-of-malignant-mesothelioma-of-the-tunica-vaginalis-managed-with-immunotherapy-and-a-review-of-the-literature>

1A



(1) Length: 3.05 cm

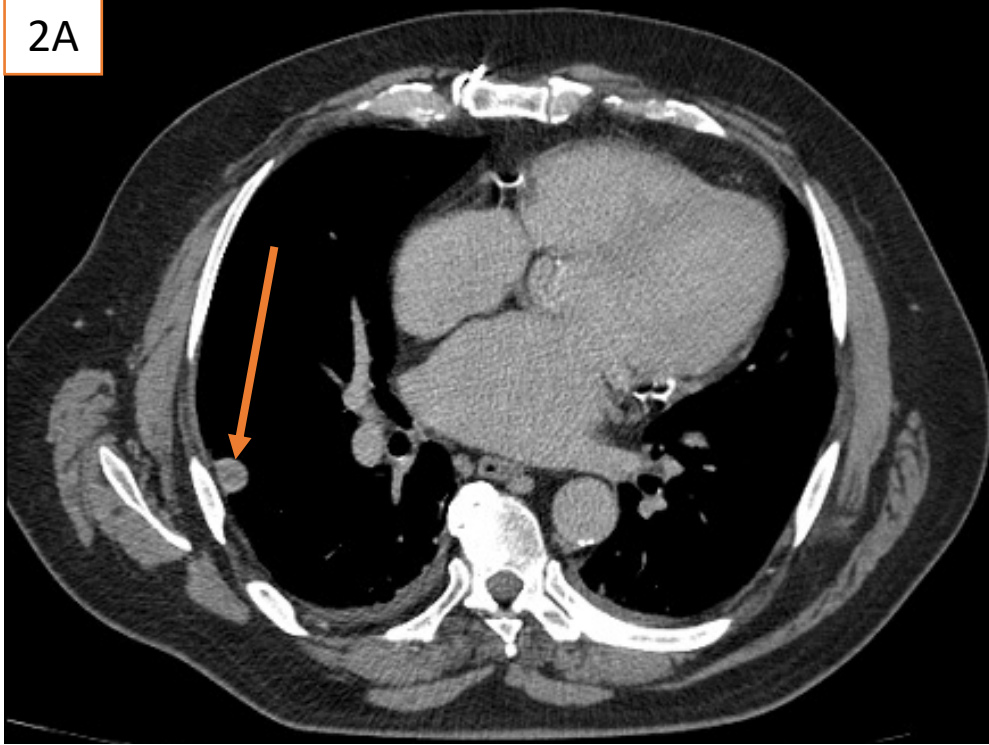
1B



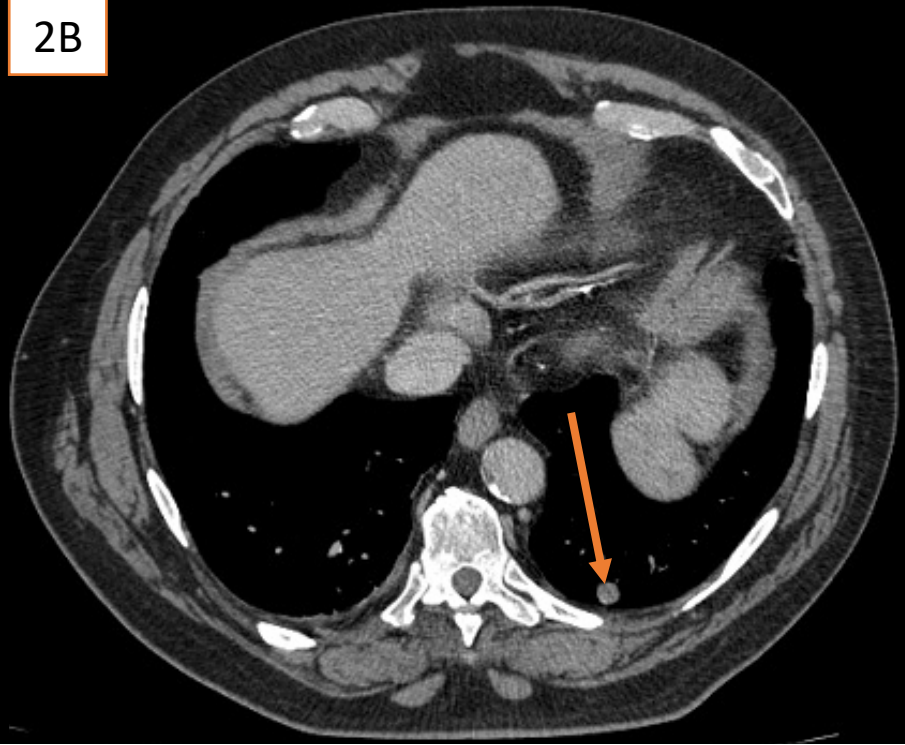
(1) Length: 2.63 cm

Bilobed mass
measuring 31
mm and 26 mm
respectively

2A



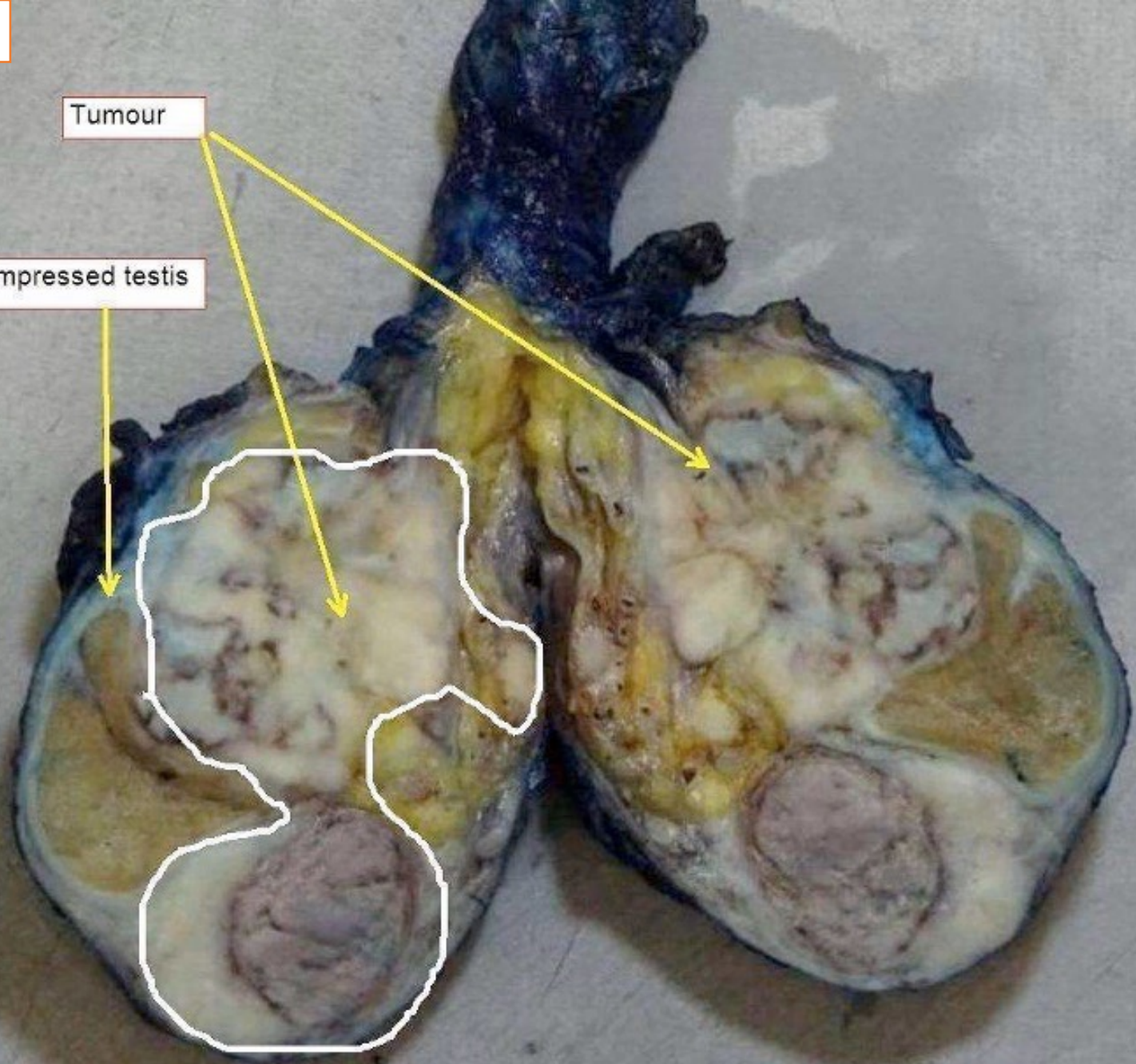
2B

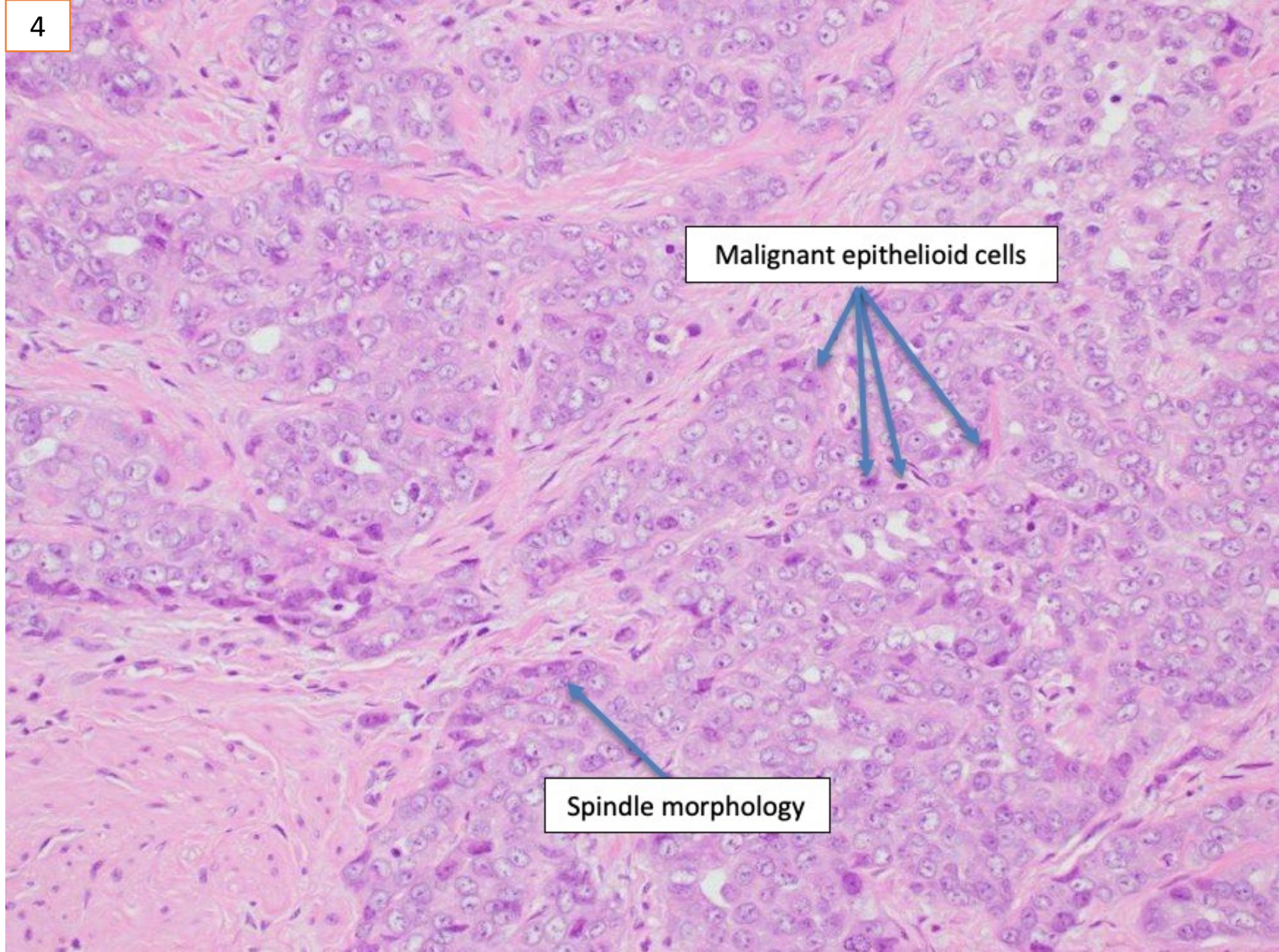


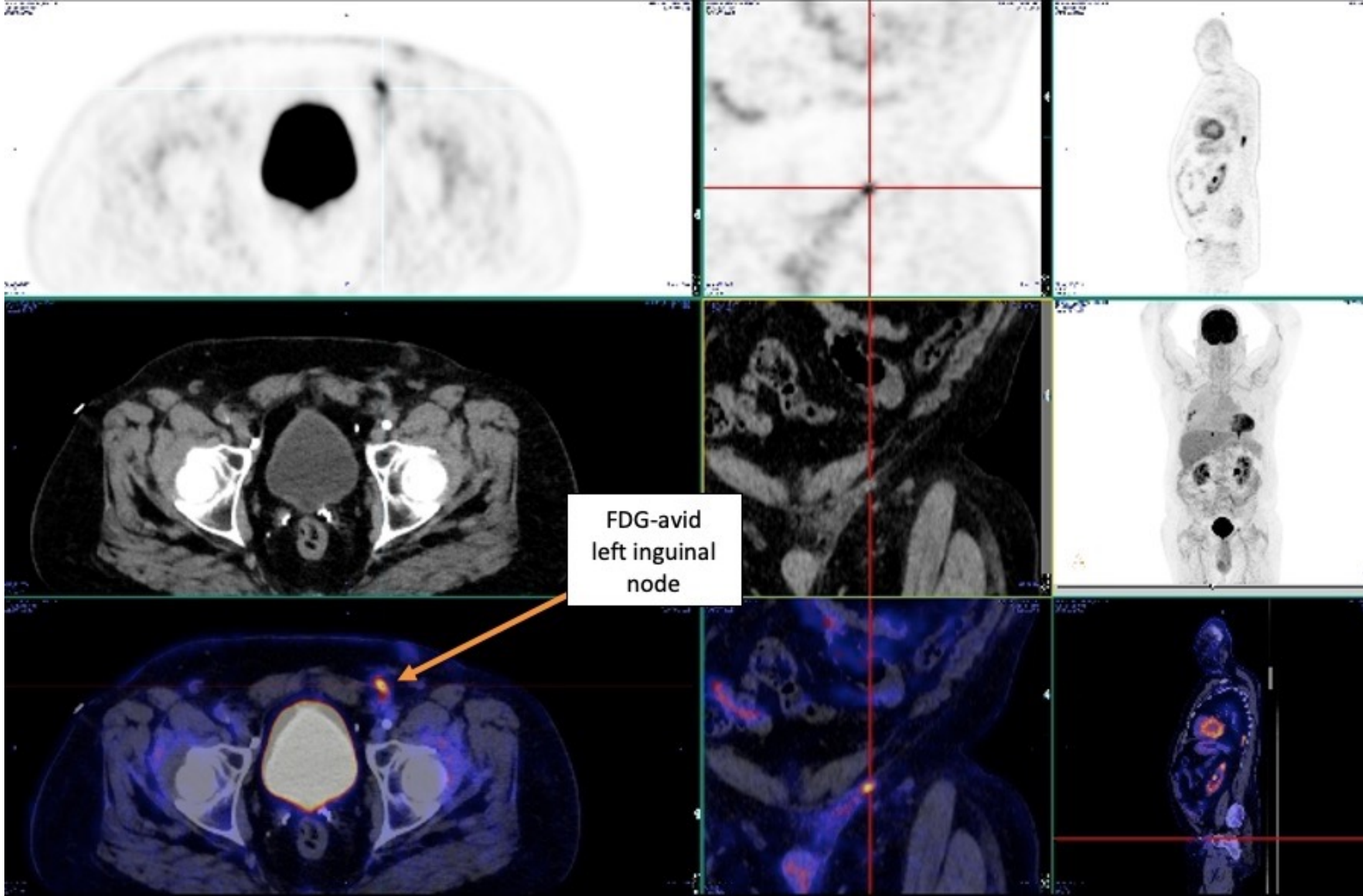
3

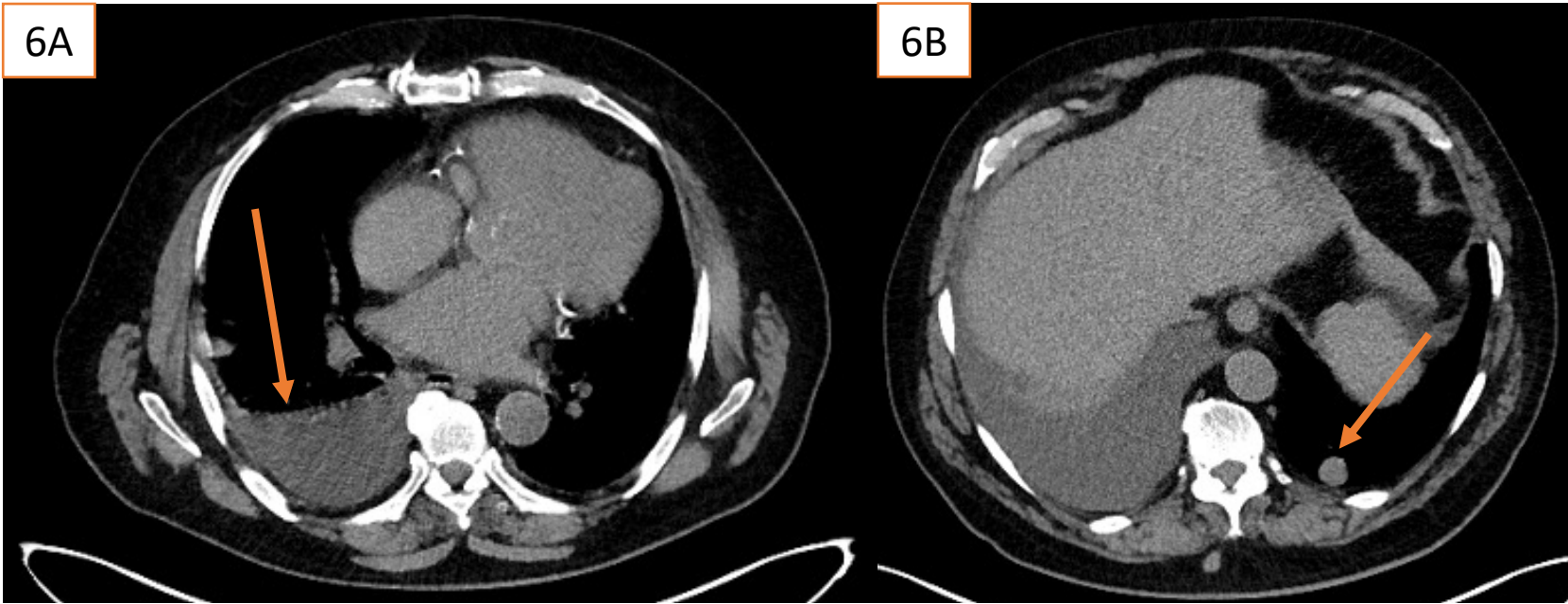
Tumour

Compressed testis

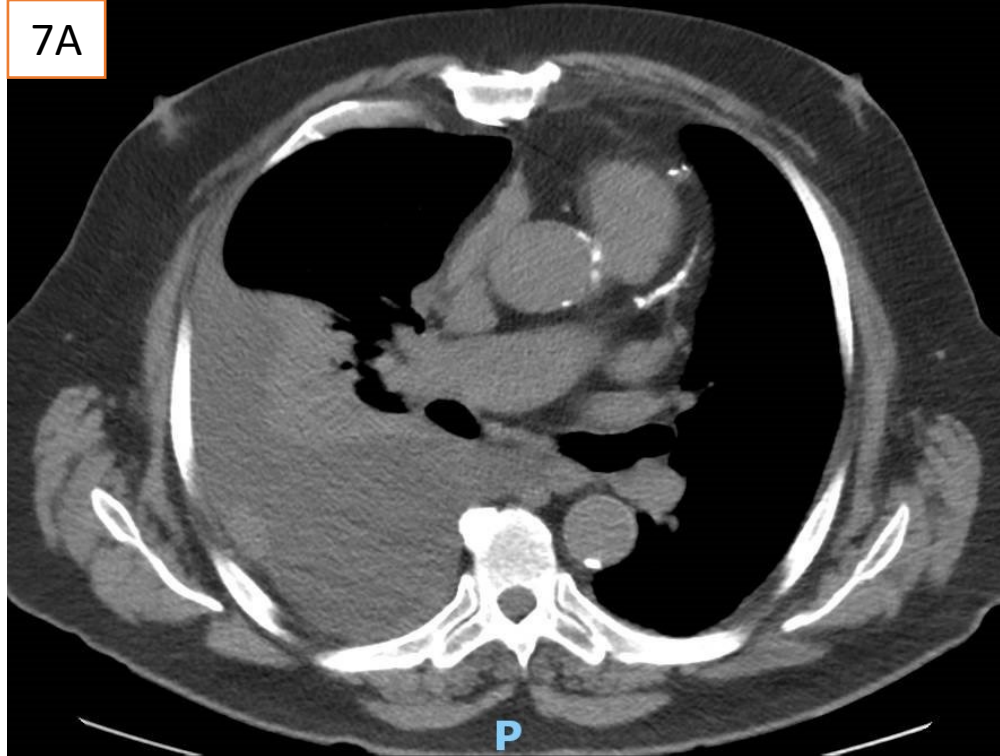




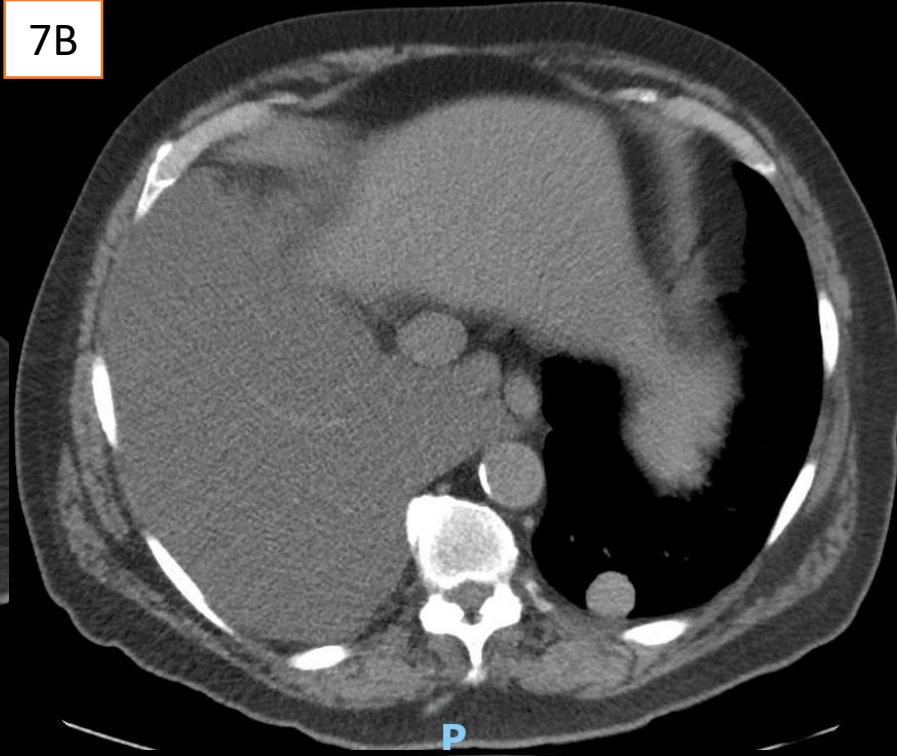




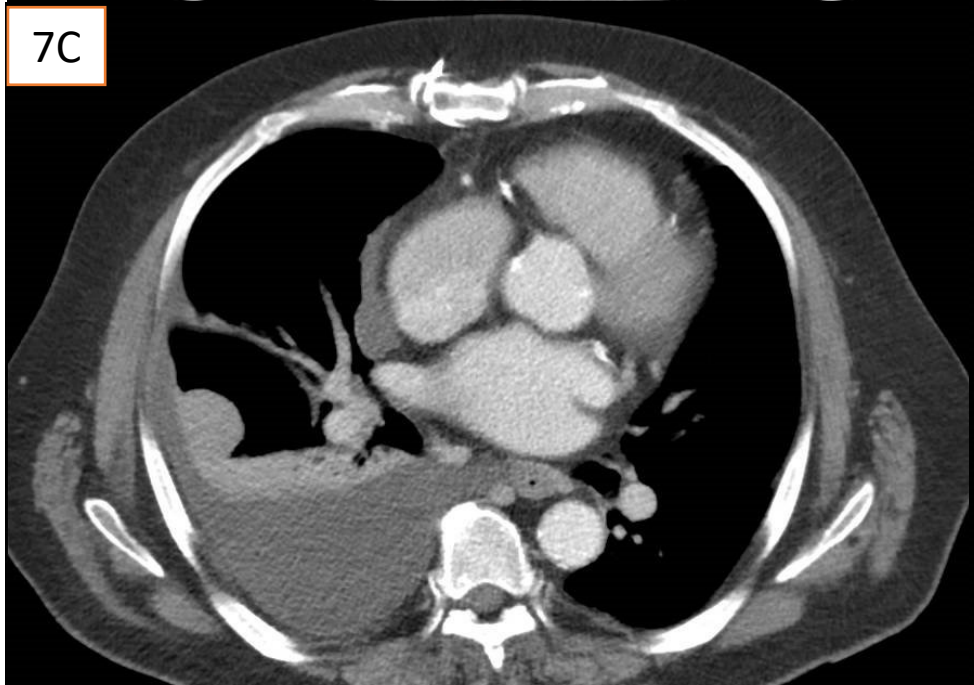
7A



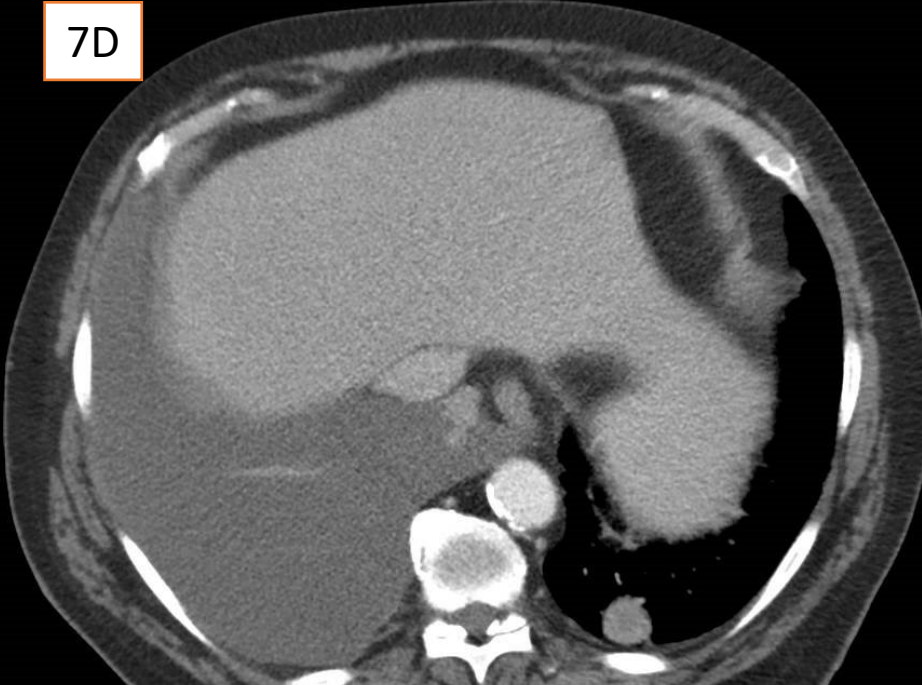
7B

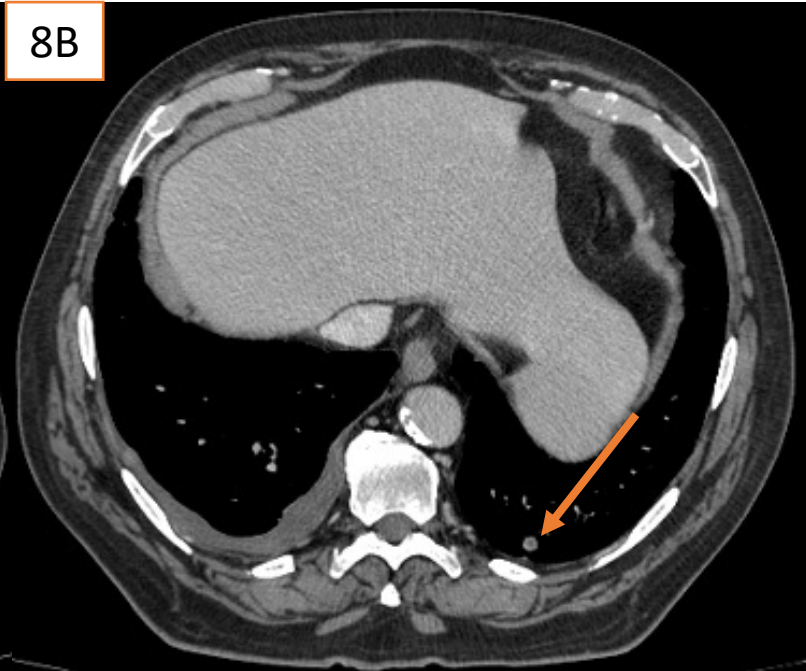
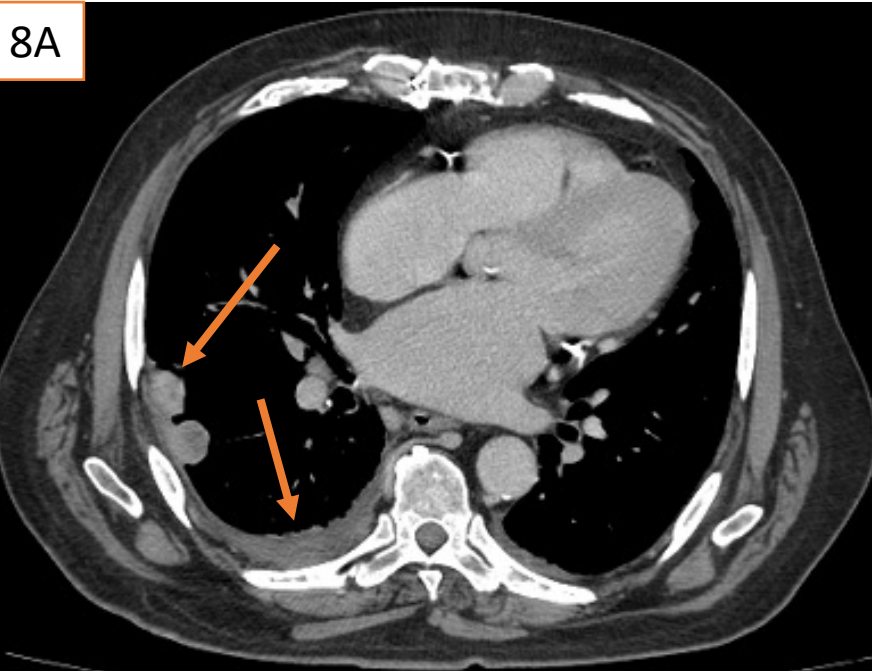


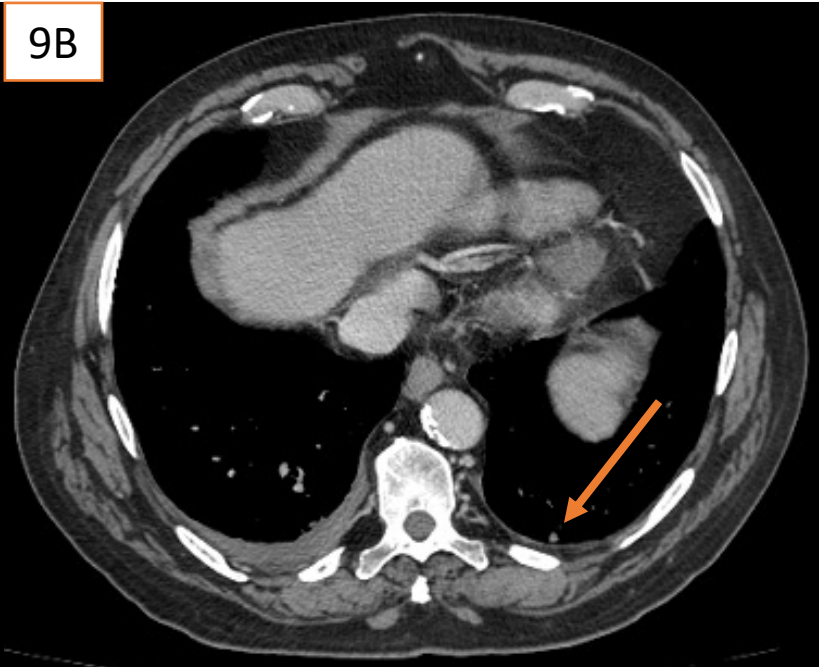
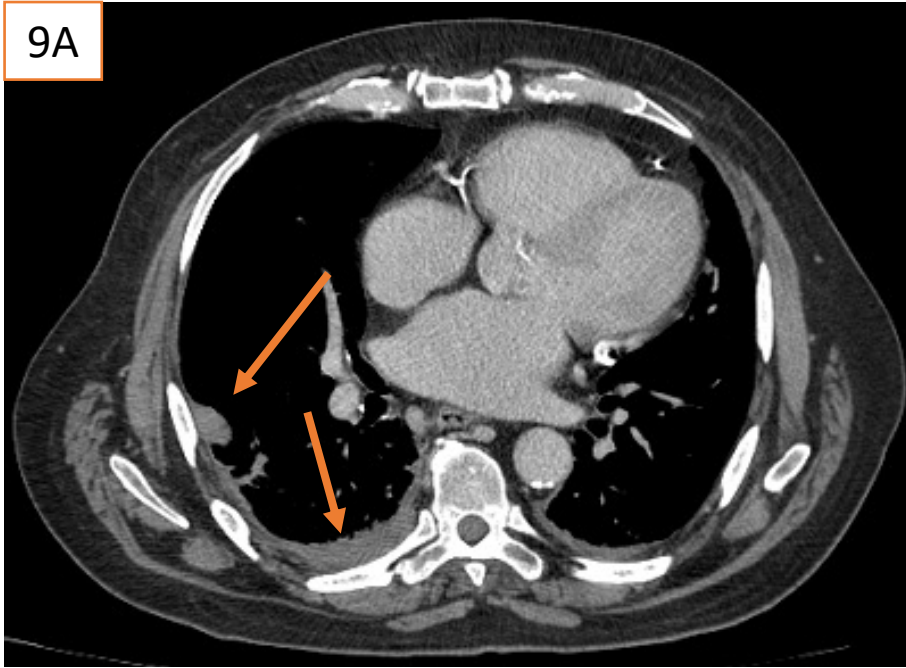
7C



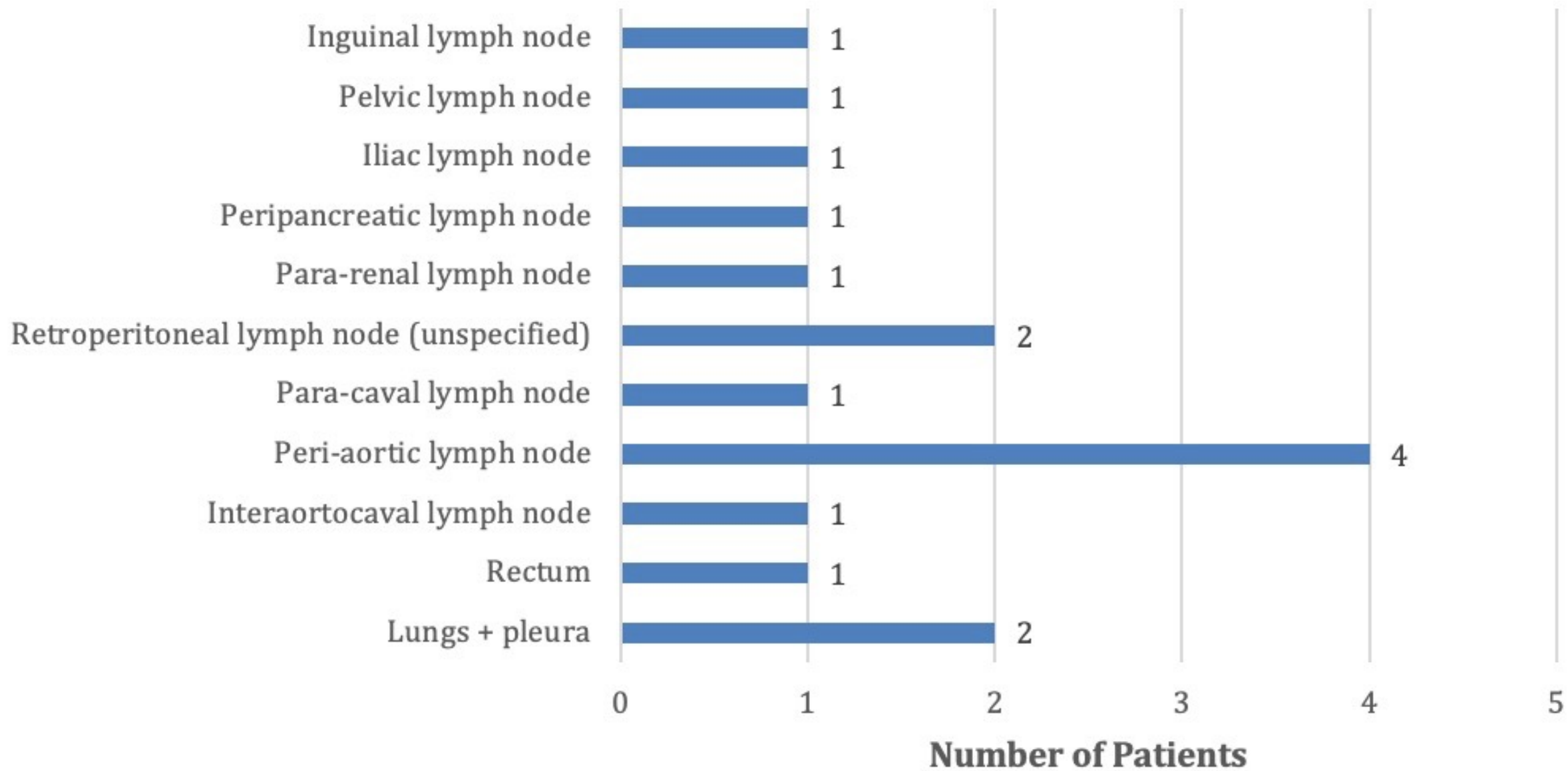
7D

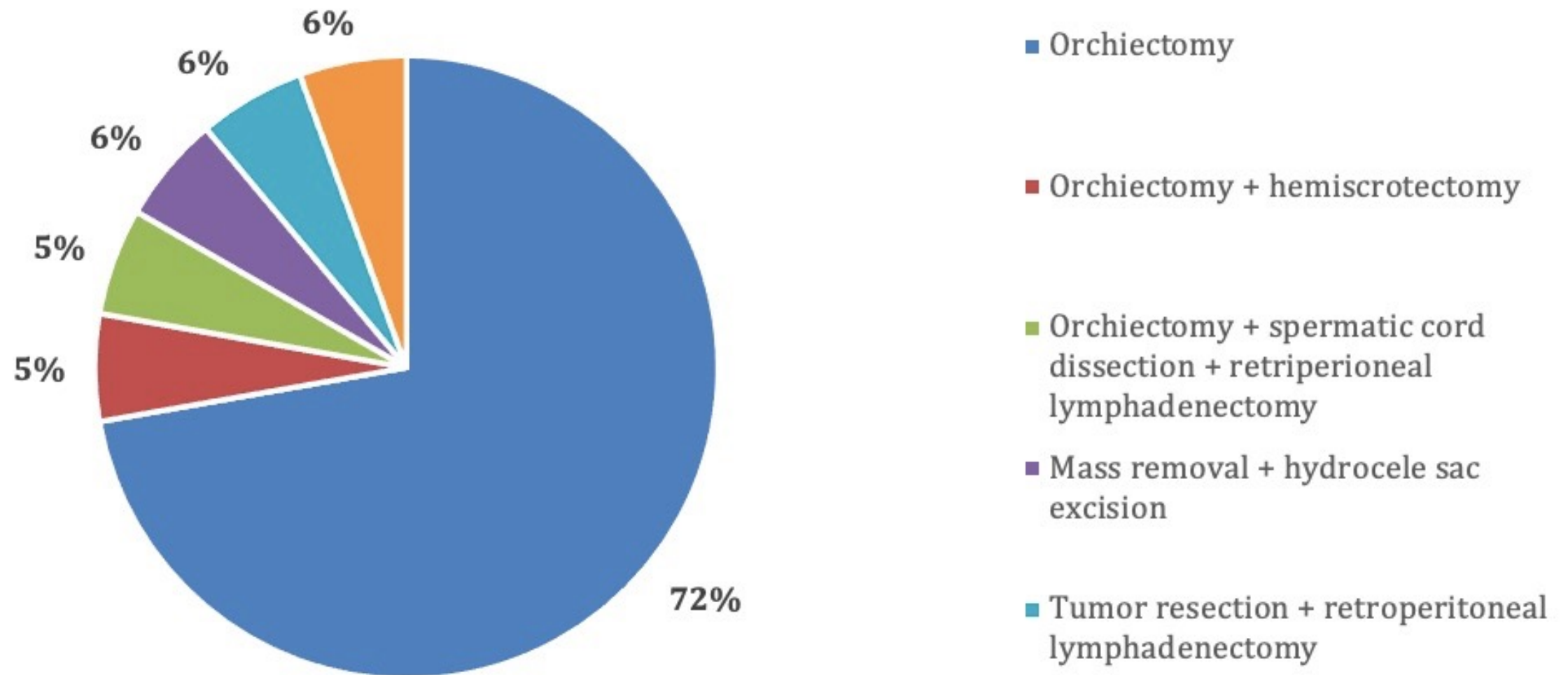




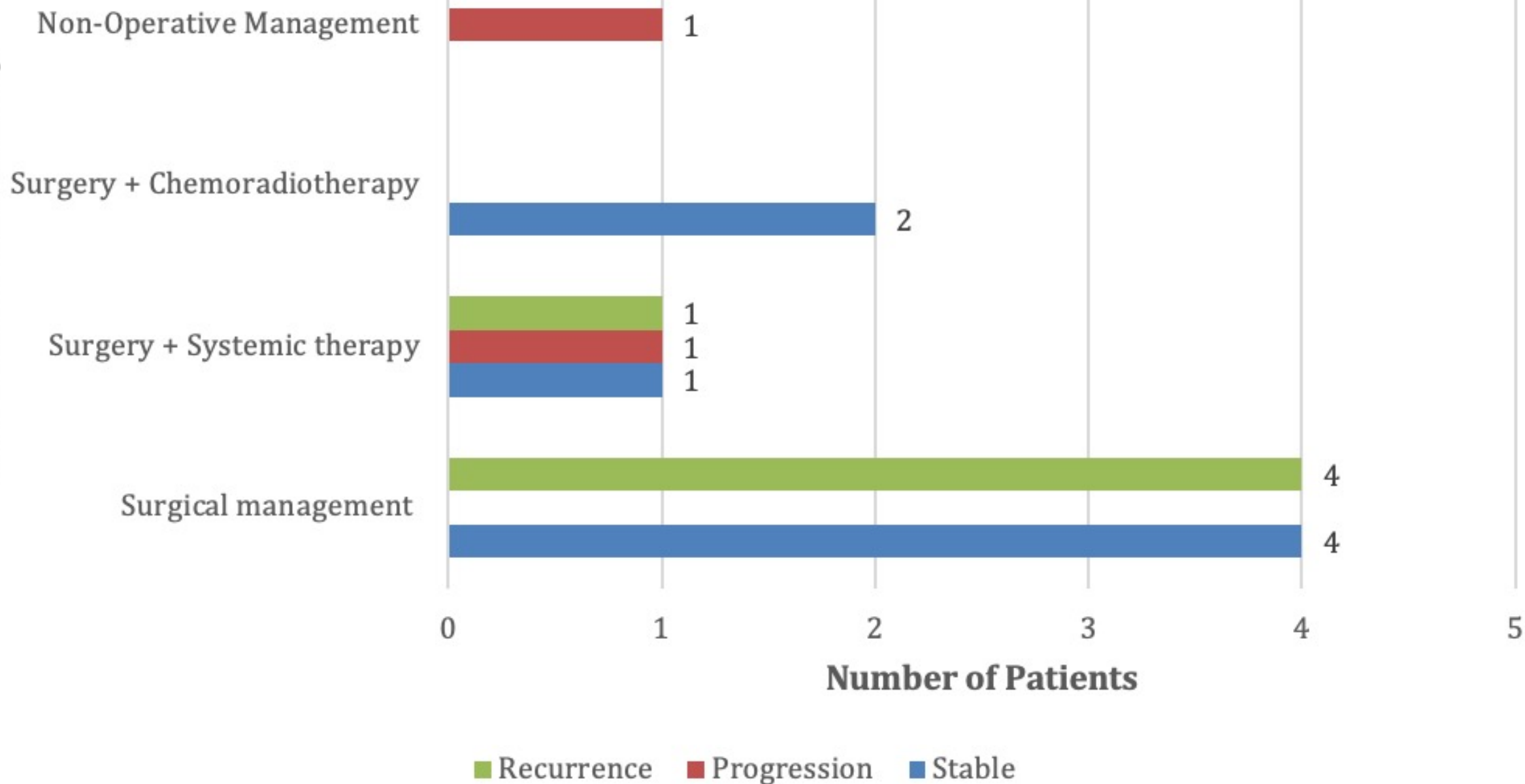


Site of Metastasis

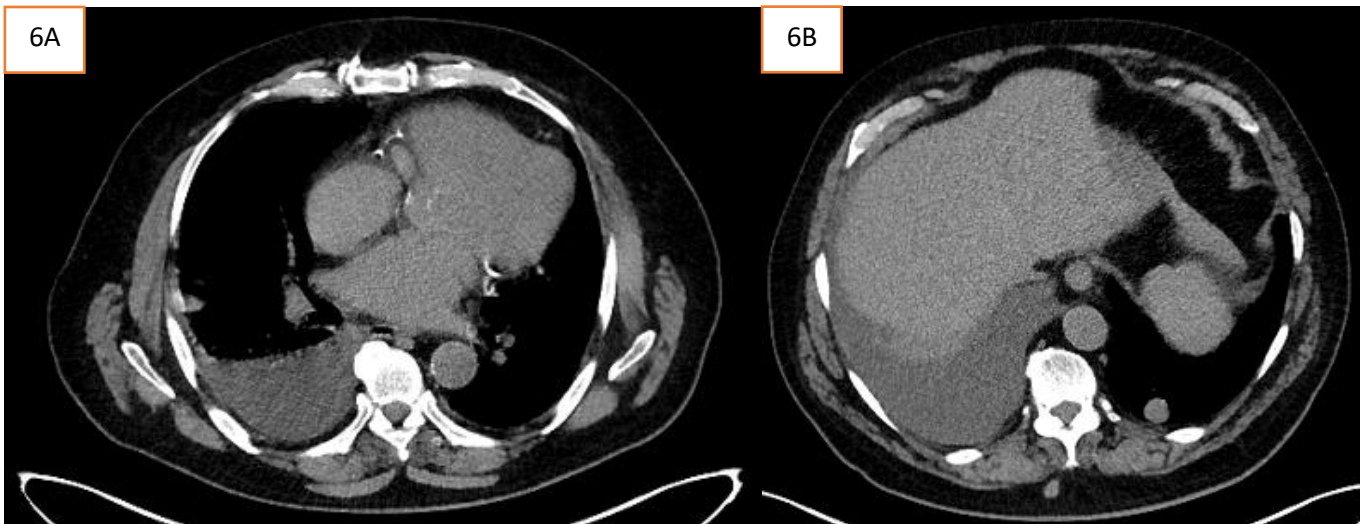
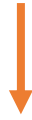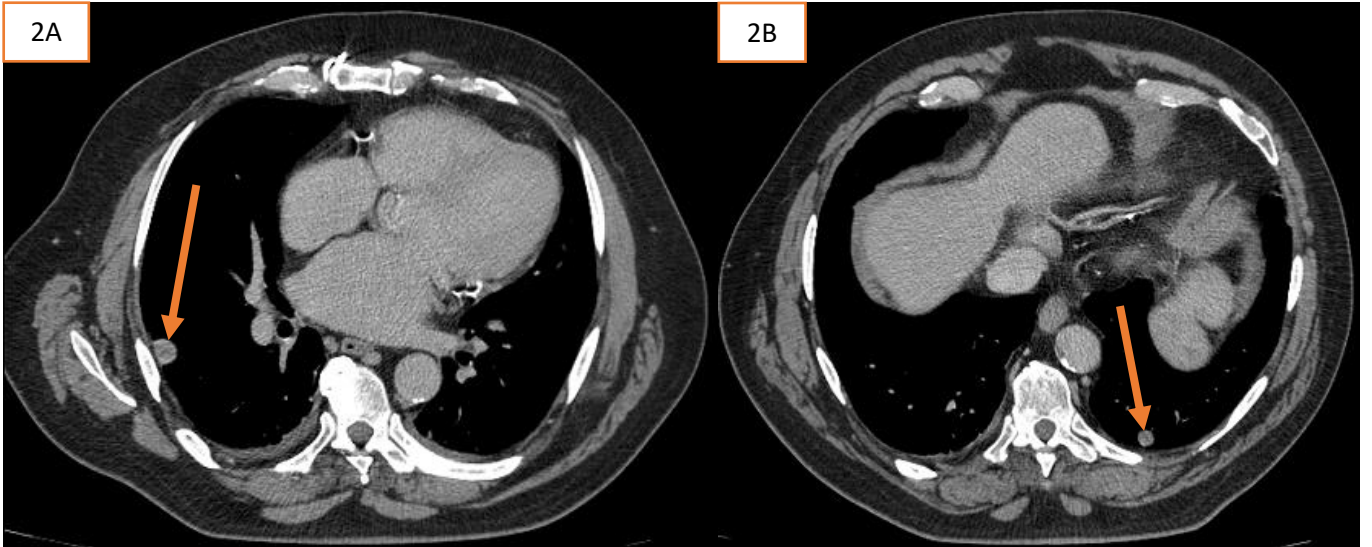


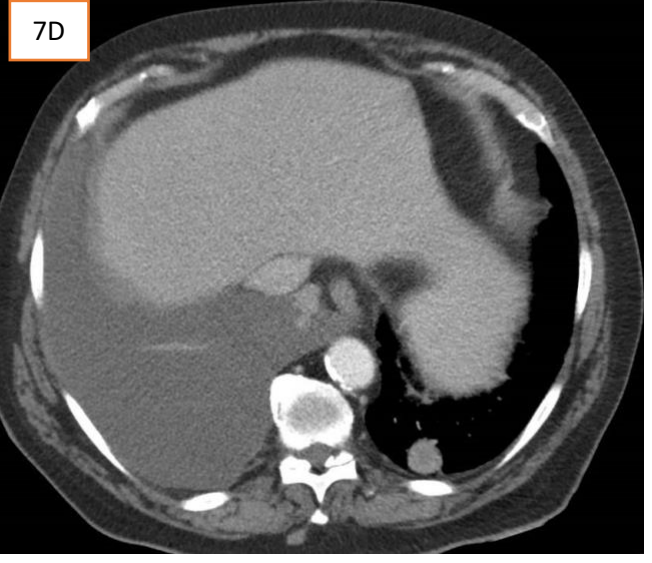
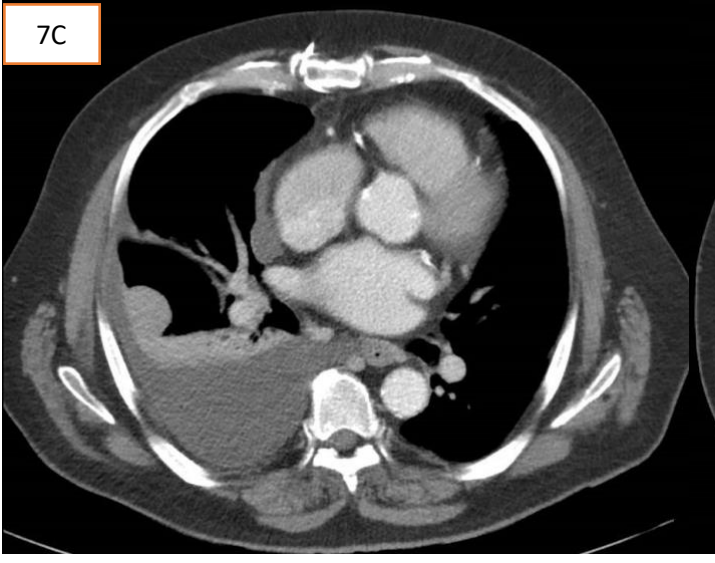
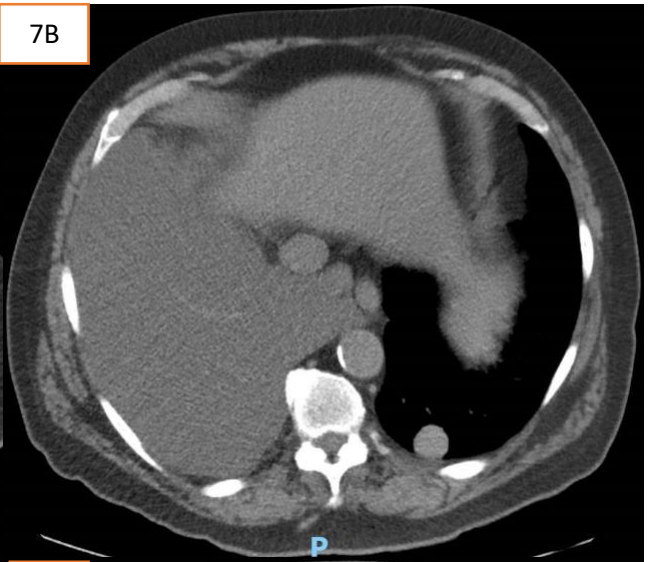
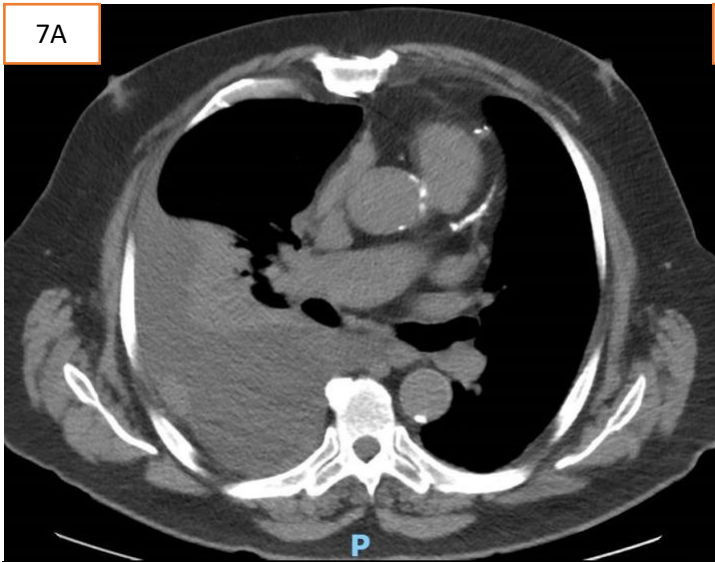


Initial Treatment Modality

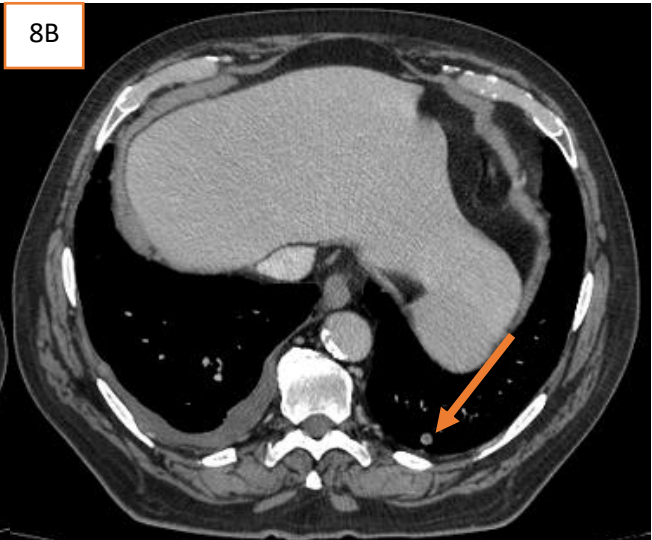
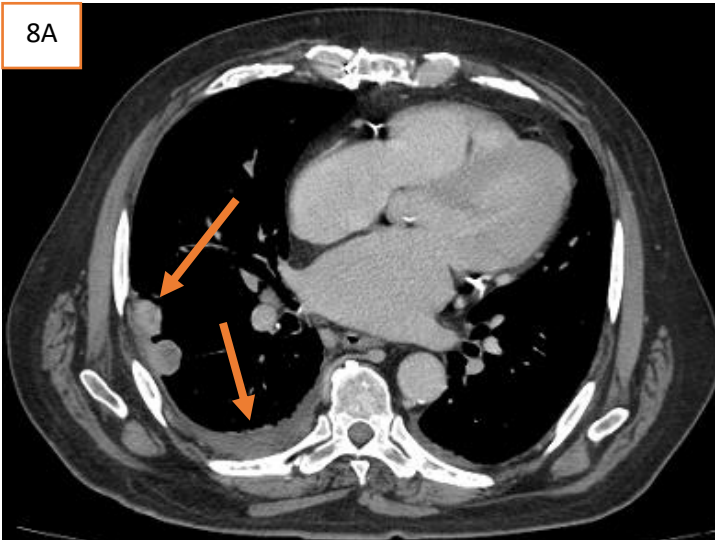
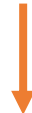

CT Chest Timeline

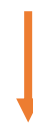



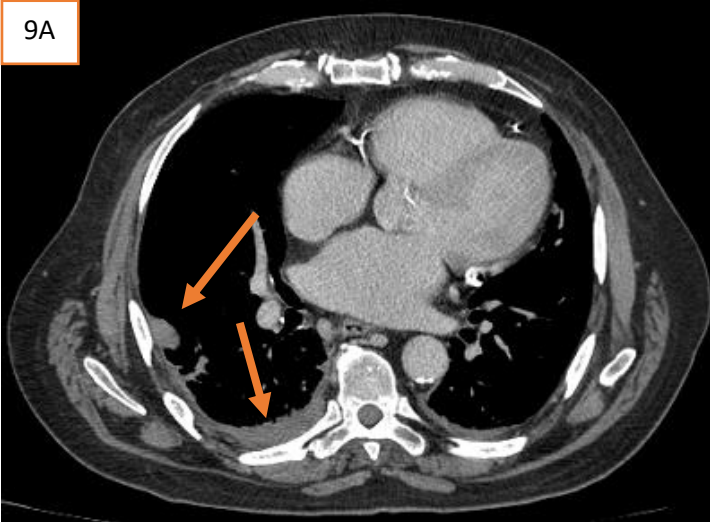
July 2022 (one week post C1D1)



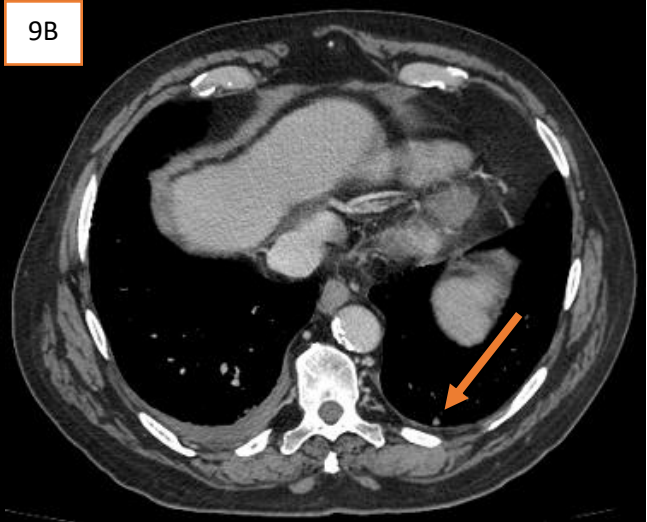
October 2022 (three months on treatment)



9A



9B



January 2023 (six months on treatment)