

# Diagnosis of congenital bronchobiliary fistula in children by bilirubin crystallization in the bronchoalveolar lavage fluid: A case report and literature review

Guangli Zhang<sup>1</sup>, Chong jie Wang<sup>1</sup>, Zhili Wang<sup>1</sup>, Xiaoyin Tian<sup>1</sup>, Yuanyuan Li<sup>1</sup>, Qinyuan Li<sup>1</sup>, Xiujuan Xu<sup>1</sup>, Hao Ding<sup>1</sup>, Jin Zhu<sup>1</sup>, Jian Luo<sup>1</sup>, and Zhengxiu Luo<sup>1</sup>

<sup>1</sup>no affiliation

February 21, 2023

## Abstract

**Background:** Congenital bronchobiliary fistula (CBBF) is a rare disease with abnormal connection between the biliary tract and the bronchus. The misdiagnosis rate of CBBF is high, delayed surgery may induce poor outcome. **Case presentation:** We reported a girl with CBBF who was confirmed via bronchoscopy and chest computed tomography (CT). The girl was 7-month-old admitted to the hospital with “recurrent pneumonia”. Bilirubin crystallization detection was positive in the bronchoalveolar lavage fluid (BALF). CT images showed the abnormal traffic between the biliary tract and the right main bronchus, the girl was diagnosed with CBBF and recovered after surgical operation. **Literature search:** A total of 27 cases were collected, 14 (51.8%) cases were diagnosed in the neonatal period, 9 (33.3%) patients were diagnosed in infancy. CBBF was more common in female (19/27, 70.3%). The specific manifestations were bilious sputum (24/27, 88.9%) and bilious vomiting (7/27, 22.2%). Recurrent pneumonia (9/27, 33.3%) was common clinical manifestations. The most abnormal fistula originates different location around the carina was right main bronchus (21/27, 77.8%). There were 23(85.2%) cases recovered after surgical operation and 4(14.8%) cases with severe comorbidities/complications died. **Conclusions:** CBBF should be suspected in infants with bilious sputum. Bronchoscopy plays crucial role in preoperative evaluation and postoperative follow-up. With early diagnosis and surgery, the prognosis is quite well for CBBF patients without severe biliary malformation and/or severe postoperative complications.

## Diagnosis of congenital bronchobiliary fistula in children by bilirubin crystallization in the bronchoalveolar lavage fluid: A case report and literature review

Guangli Zhang<sup>1</sup>, Chongjie Wang<sup>1</sup>, Zhili,Wang<sup>1</sup>, Xiaoyin Tian<sup>1</sup>, Yuanyuan Li<sup>1</sup>, Qinyuan Li<sup>1</sup>, Xiujuan Xu<sup>1</sup>, Hao Ding<sup>2</sup>, Jin Zhu<sup>3</sup>, Jian Luo<sup>1</sup>, Zhengxiu Luo<sup>1\*</sup>

\*Correspondence: luozhengxiu816@hospital.cqmu.edu.cn

**Abstract: Background:** Congenital bronchobiliary fistula (CBBF) is a rare disease with abnormal connection between the biliary tract and the bronchus. The misdiagnosis rate of CBBF is high, delayed surgery may induce poor outcome. **Case presentation:** We reported a girl with CBBF who was confirmed via bronchoscopy and chest computed tomography (CT). The girl was 7-month-old admitted to the hospital with “recurrent pneumonia”. Bilirubin crystallization detection was positive in the bronchoalveolar lavage fluid (BALF). CT images showed the abnormal traffic between the biliary tract and the right main bronchus, the girl was diagnosed with CBBF and recovered after surgical operation.**Literature search :** A total of 27 cases were collected, 14 (51.8%) cases were diagnosed in the neonatal period, 9 (33.3%) patients were diagnosed in infancy. CBBF was more common in female (19/27, 70.3%). The specific manifestations were bilious sputum (24/27, 88.9%) and bilious vomiting (7/27, 22.2%). Recurrent pneumonia (9/27, 33.3%) was common clinical manifestations. The most abnormal fistula originates different location around the carina

was right main bronchus (21/27, 77.8%). There were 23(85.2%) cases recovered after surgical operation and 4(14.8%) cases with severe comorbidities/complications died. **Conclusions:** CBBF should be suspected in infants with bilious sputum. Bronchoscopy plays crucial role in preoperative evaluation and postoperative follow-up. With early diagnosis and surgery, the prognosis is quite well for CBBF patients without severe biliary malformation and/or severe postoperative complications.

**Keywords:** Congenital bronchobiliary fistula (CBBF); bronchoalveolar lavage fluid; bilirubin crystallization; children; case report

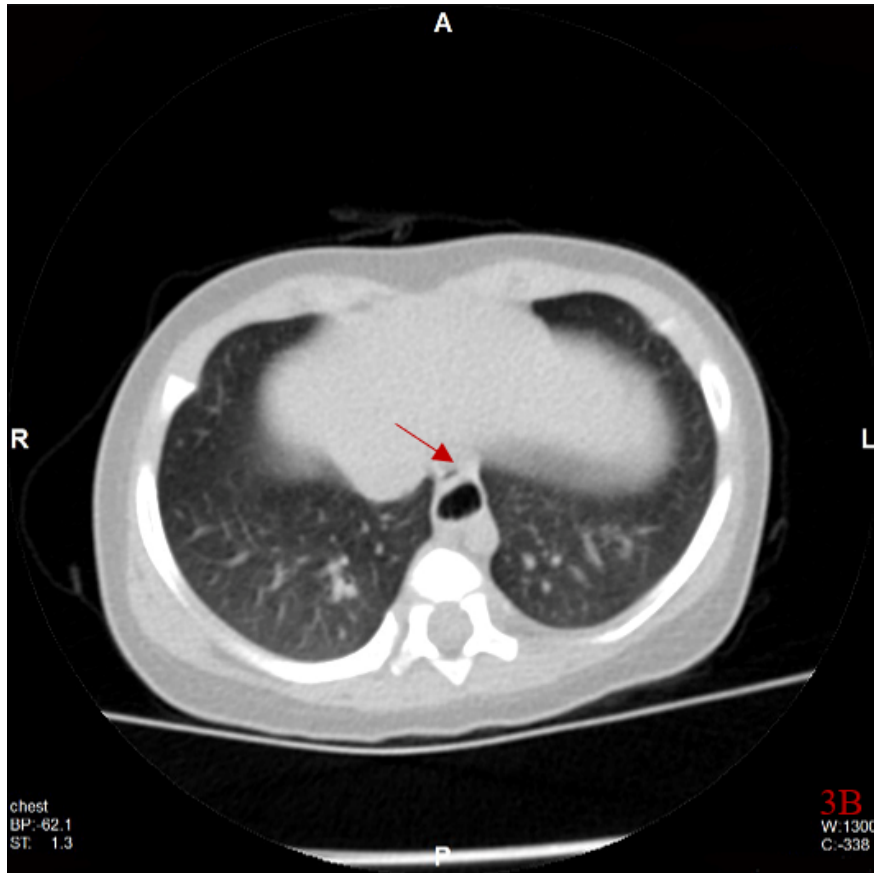
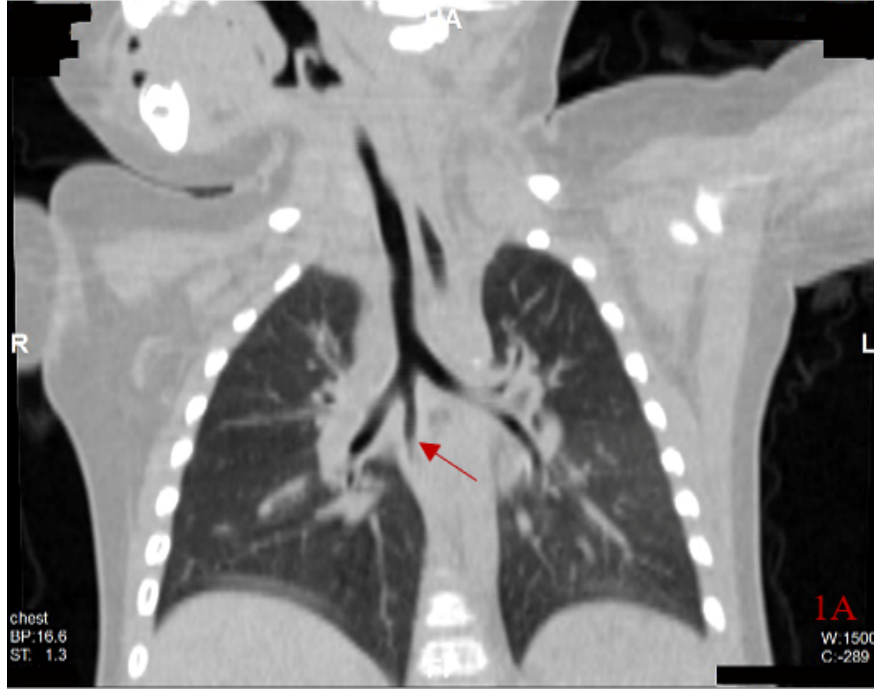
## 1 Introduction

Congenital bronchobiliary fistula (CBBF) refers to the abnormal traffic between the biliary system and the bronchial tree. CBBF is a rare disease and easily misdiagnosed as pneumonia or other diseases in clinical practice, which resulting in delayed treatment and worse outcomes<sup>[1,2]</sup>. Few studies have reported the role of bilirubin crystallization detection in the bronchoalveolar lavage fluid (BALF) for diagnosis CBBF<sup>[3]</sup>. Here, we reported an infant with recurrent pneumonia who admitted to Children's hospital, Chongqing Medical University. She was diagnosed with CBBF combined positive bilirubin crystallization detection in BALF with related chest CT images and recovered after surgery. The detection of bilirubin crystallization in BALF plays important diagnostic value in patients suspected with CBBF<sup>[3,4]</sup>. Surgery is the first choice for CBBF patients<sup>[3-6]</sup>. Next, we collected literature about patients with CBBF so as to further improve the recognition and early intervention.

### 1.1 Case presentation

A 7-month-old girl was admitted to respiratory department with persistent wet cough and recurrent wheezing. She was diagnosed with recurrent pneumonia and treated with antibiotics, bronchodilators and glucocorticoids empirically when symptoms worsen. She was full-term with normal manifestation during perinatal period. She occasionally expectorated bright-yellow sputum when drinking breast or milk. Chest computed tomography (CT) images showed an abnormal bronchial bifurcation originated from the right main bronchus (Figure 1A). Both transverse (Figure 1B) and anamorphic (Figure 1C) chest CT indicated gas shadow anterior to the esophagus at the diaphragm level. Yellow, serous secretions emerging from an anomalous orifice located at the right main bronchus via bronchoscopy (Figure 2A and 2B). The bright-yellow BALF was obtained and tested for bilirubin with positive detection. The contrast agent meglumine was injected through the anomalous orifice via flexible bronchoscope. Chest CT examination showed the contrast agent entered the abnormal bronchus and traveled downward, passing through the left hepatic duct, the common hepatic duct and common bile duct (Figure 3). The girl was diagnosed with congenital bronchobiliary fistula (CBBF) based on these findings. She had operation to remove the anomalous fistula. During the ten months following-up, the girl was absent from wet cough, wheezing and pneumonia. Chest computed tomography examination demonstrated that the anomalous orifice and lung shadow disappeared (Figure 1D). Bronchoscopy showed an anomalous diverticulum (Figure 2C) and the BALF was colorless with no bilirubin presented.

Pathological examination showed tubular structure of cartilage and muscle, lined with stratified squamous epithelium, pseudostratified columnar ciliated epithelium and submucosal glands (Figure 4).



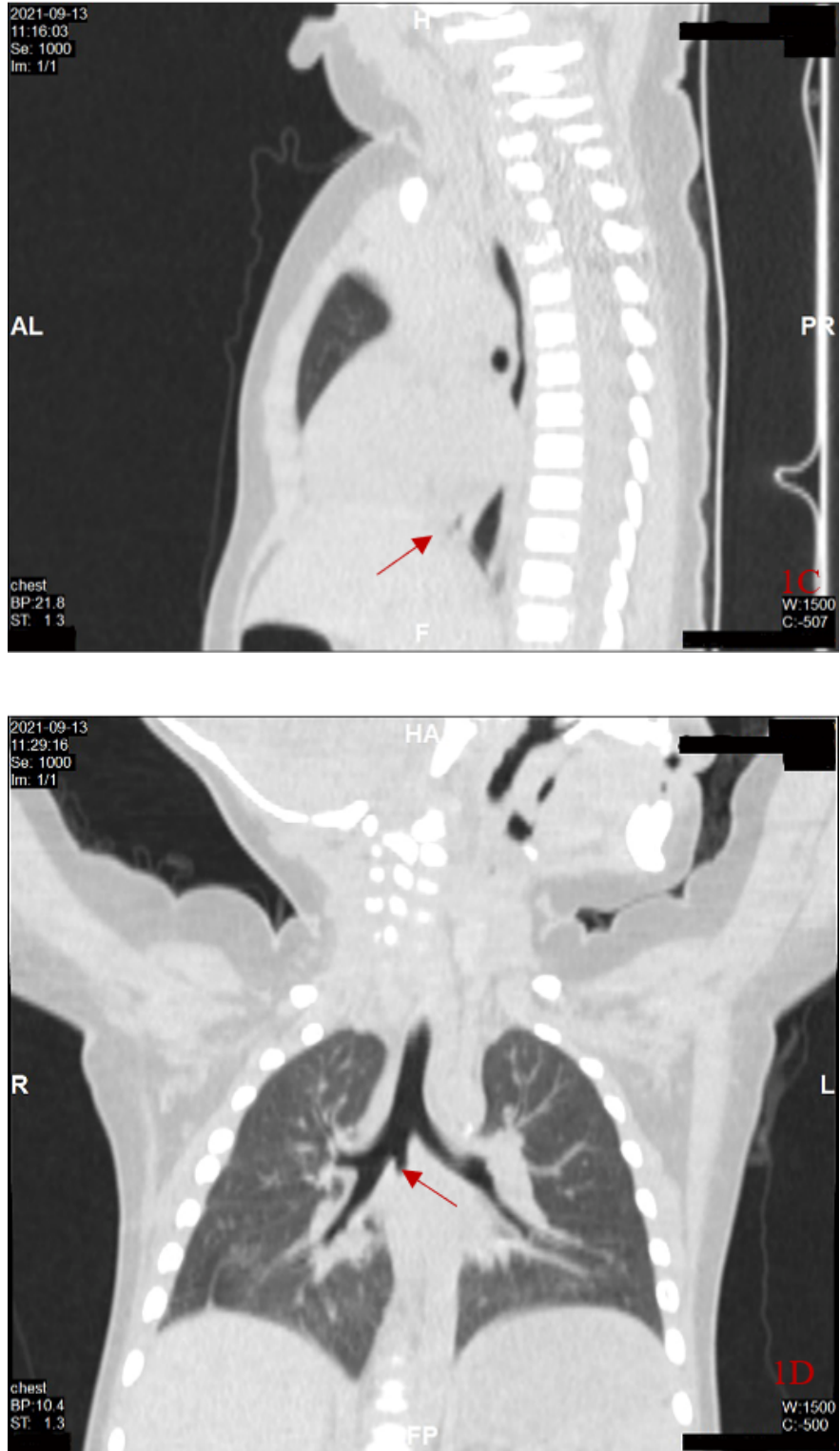
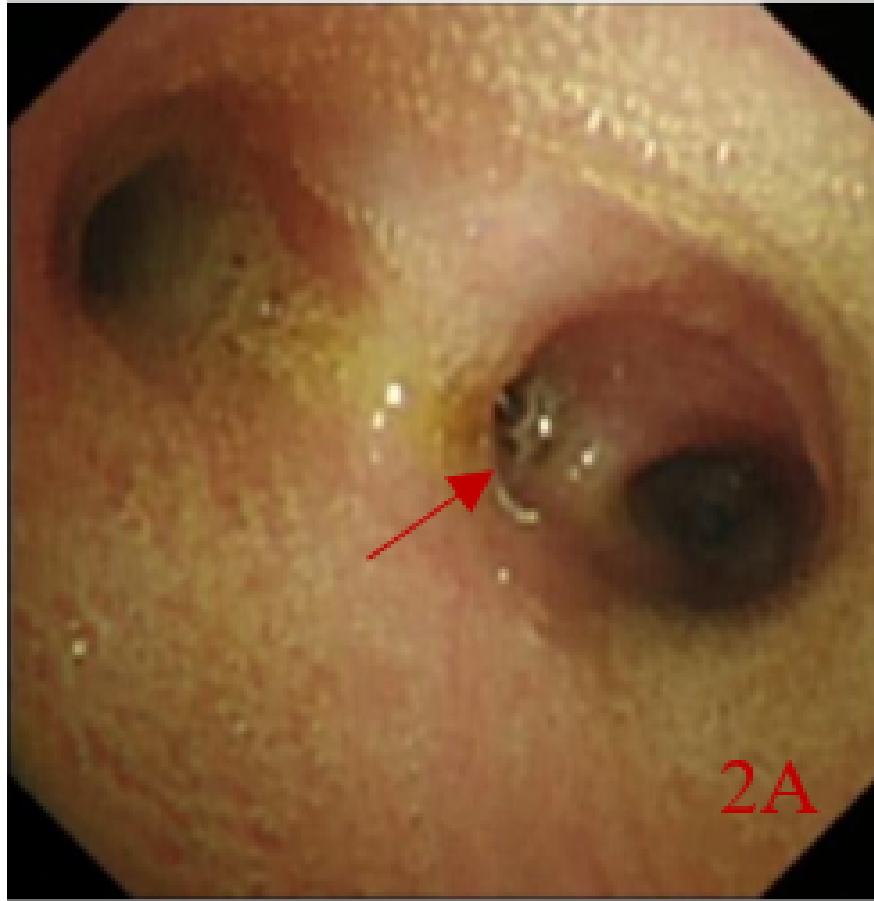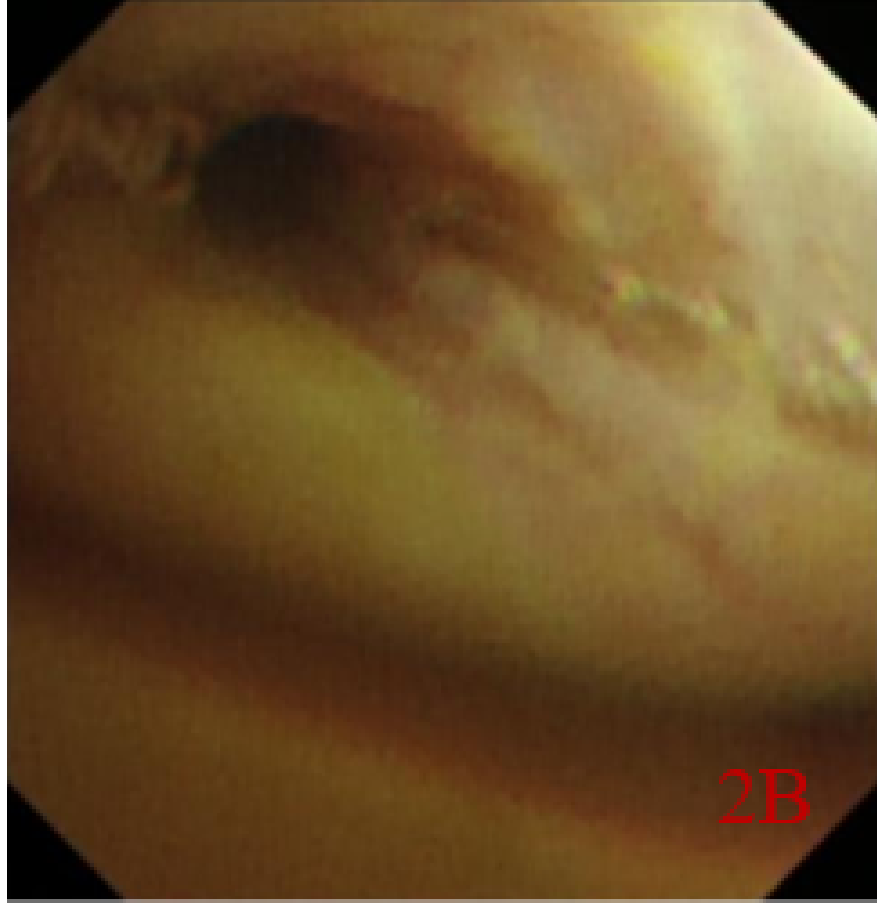


Figure 1. A: Airway reconstruction showed a tubular shadow at the terminal of the right main bronchus before surgery (red arrow); B: Transverse view showed a gas shadow in front of the esophagus at the level

of the diaphragm (red arrow); C: Loss of shape showed the diaphragm with gas shadow in front of the esophagus (red arrow); D: Airway reconstruction showed tubular shadow disappeared with a blind end after surgery (red arrow)





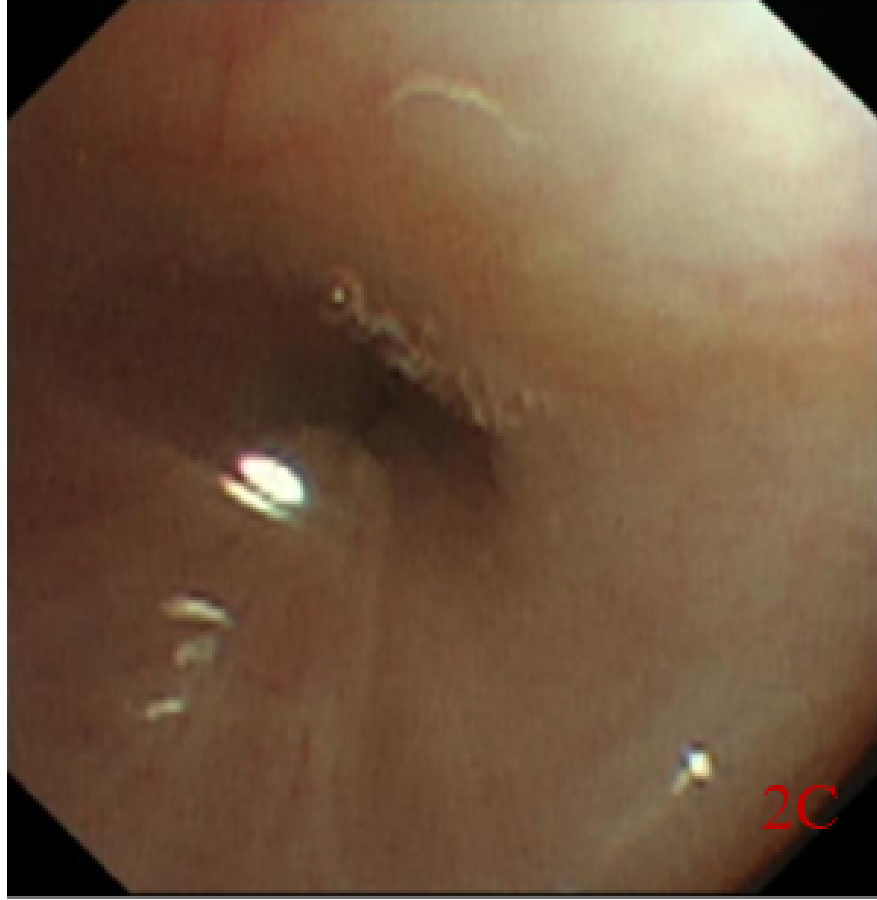
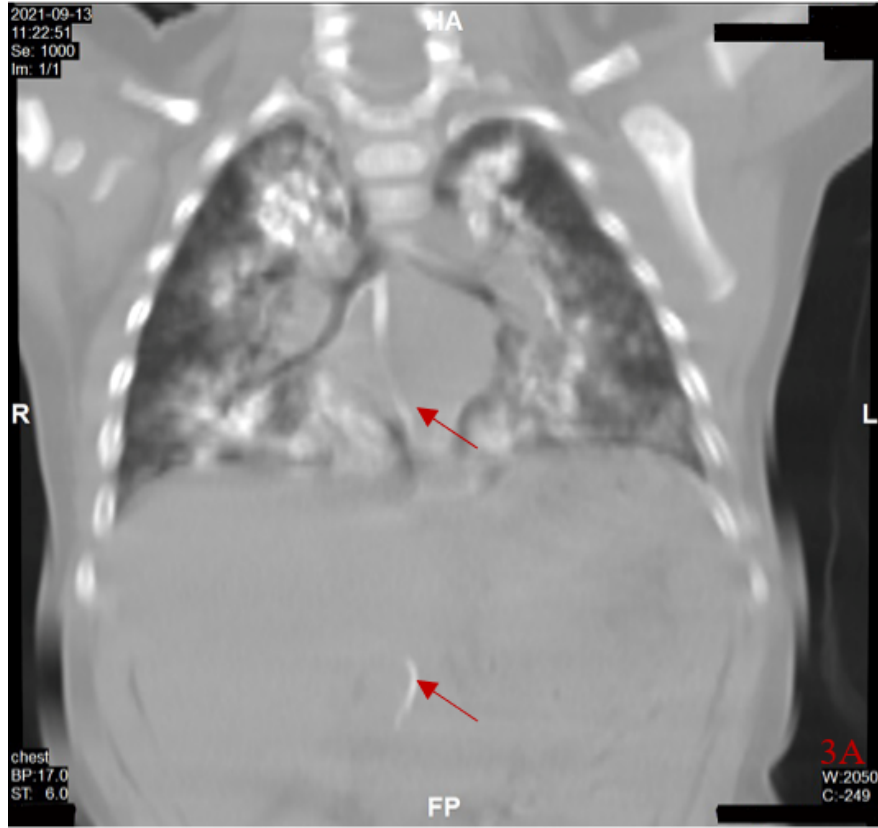
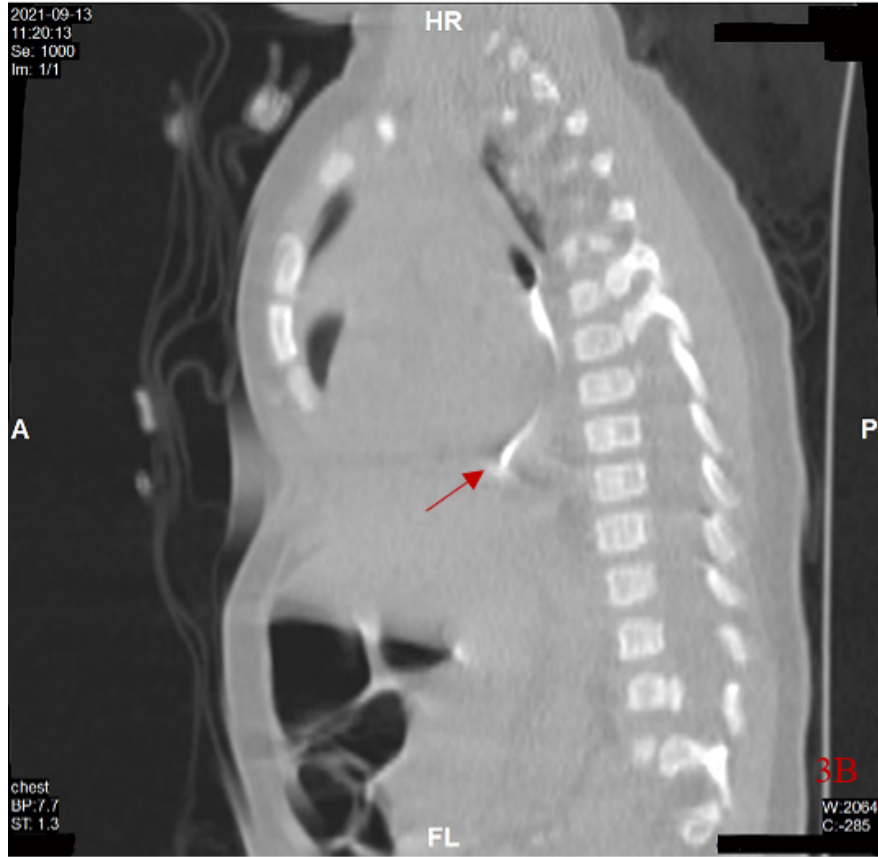


Figure 2. A: An anomalous orifice was found at the right main bronchus under bronchoscopy (red arrow); B: Yellow secretions from the anomalous orifice (before surgery); C: an anomalous diverticulum after surgery







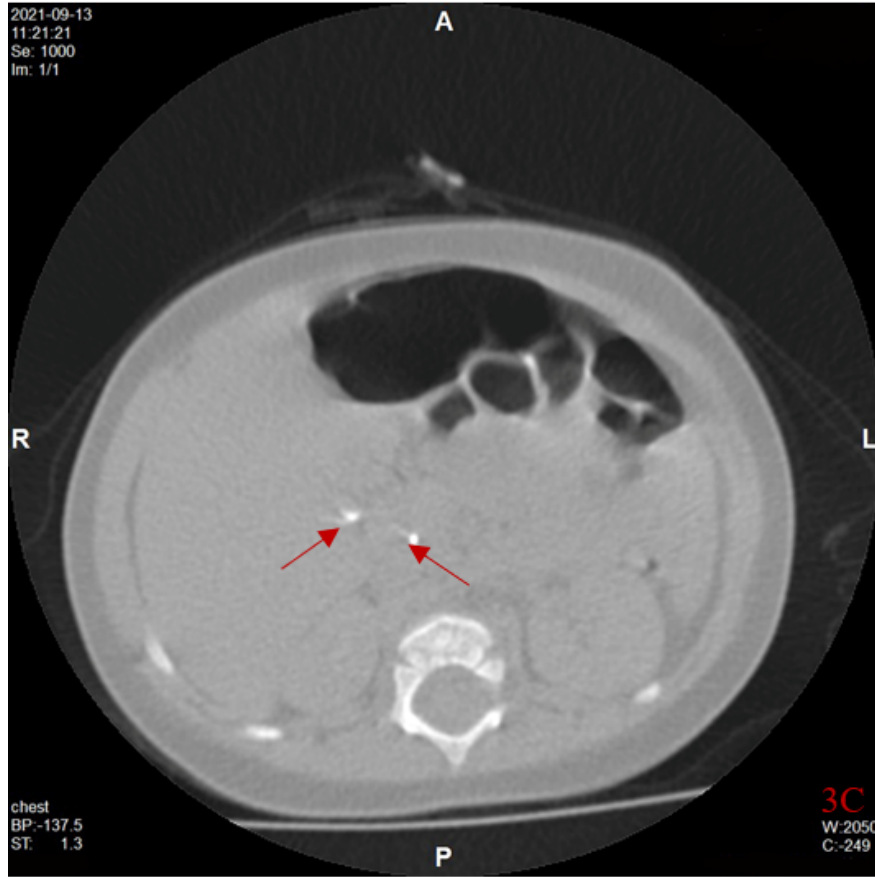


Figure 3. A: Airway reconstruction showed that the contrast agent entered the abnormal bronchus and traveled downward (red arrows); B: The contrast agent entered the abnormal bronchus and traveled down through the diaphragm (red arrow). C: Cross-sectional view showed the inflow of contrast agent into the common bile duct and common hepatic duct (red arrows)

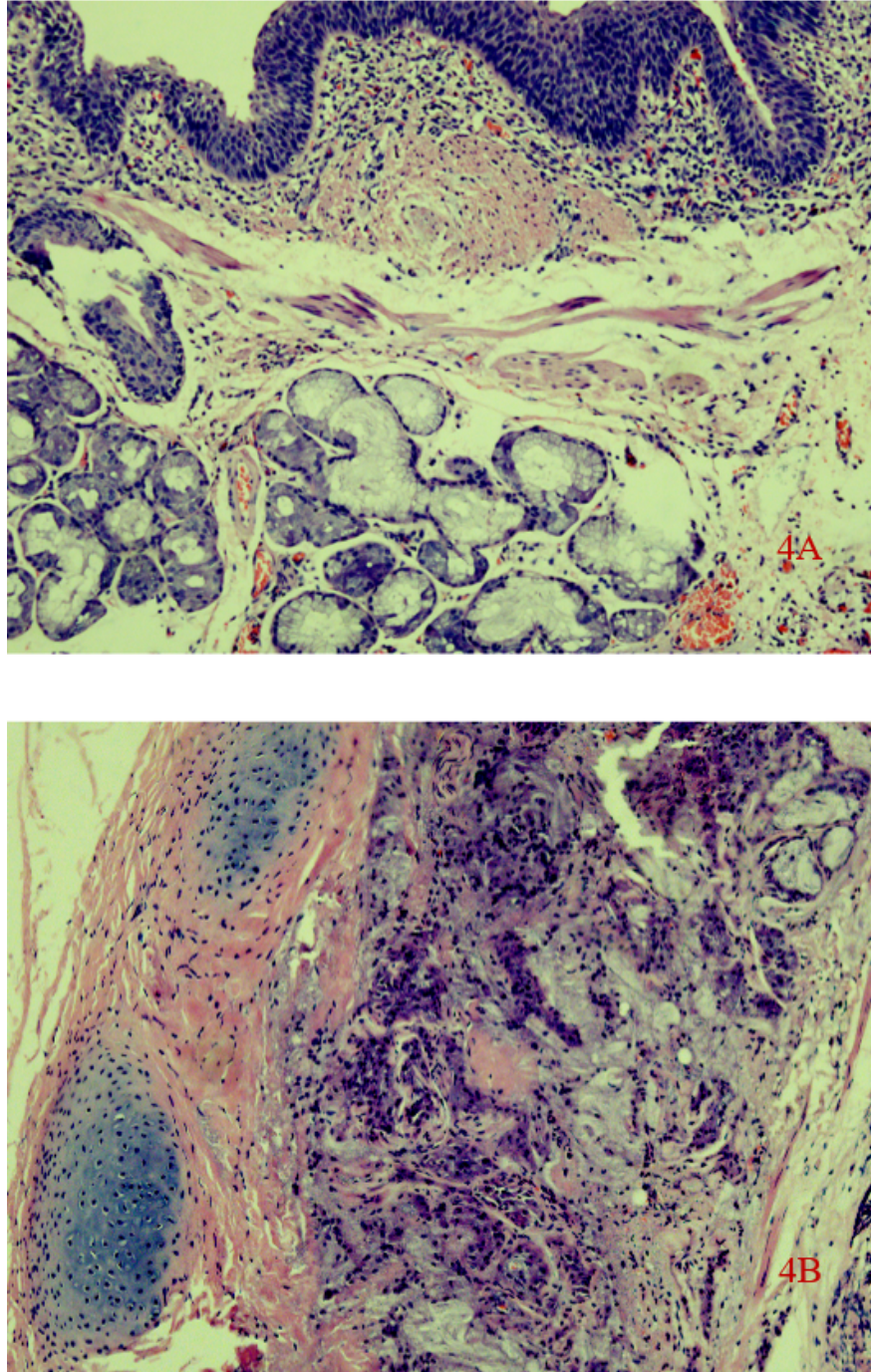


Figure 4. Pathological examination of the anomalous fistula A: tubular structure of cartilage and muscle, lined with stratified squamous epithelium, pseudostratified columnar ciliated epithelium and submucosal glands, inflammatory infiltration of lymphocytes in the mucosal lamina propria (HE stain,  $\times 100$ ); B: glandular hyperplasia, dominated by mucus glands. Mucus exuded into the periductal interstitial space (HE stain,  $\times 100$ ).

## 1.2 Statement of ethics

Informed consent was obtained from the patient’s parents who agreed to publish this case, and the study was approved by the Ethics Committee of Children’s Hospital of Chongqing Medical University (China).

### 1.3 Literature review

#### Information sources and search key words

Using the search terms “congenital bronchobiliary fistula” OR “bronchobiliary fistula”, Medline (via PubMed), Embase and web of science databases, China National Knowledge Infrastructure (CNKI) and Wanfang were searched. We also searched Chinese Medical Care Repository, searches for relevant articles were performed with the following items: “congenital bronchobiliary fistula” OR “bronchobiliary fistula. Searches were limited to articles published in English till March 31, 2022.

#### Eligible criteria

##### Inclusion:

Congenital bronchobiliary fistula patients, not restricted by age, gender, disease course, race, region and other factors;

##### Exclusion:

- 1)Secondary bronchobiliary fistula patients;
- 2)Article not published in Chinese or English;
- 3)In vitro and in vivo studies;
- 4)Conference abstracts;
- 5)Full-text or data cannot be extracted

#### Searching results

Searches of literatures initially identified 1149 potentially relevant records. Following review of the title and abstract, 1051 records were excluded, and a further 73 duplicated records were excluded, 25 records were included. Therefore, 19 English articles and 6 Chinese articles were included, a total of 26 cases<sup>[4-28]</sup>. Combined with 1 case in this article, a total of 27 cases of CBBF were enrolled. The clinical data summary table is shown in Table 1.

Figure 5. Flow diagram of congenital bronchobiliary fistula

Table1. All cases of congenital bronchobiliary fistula reported to data

N	Year	Author	Type of fistula	Age	Sex	Diagnostic method	Comorbidity	Operative method	Therapeutic effect
1	2021	Meng EY et al	Right main bronchus	3d	F	Bronchoscopy and CT	biliary atresia	Surgical excision and ligation + Roux En-Y anastomosis	Successful

N	Year	Author	Type of fistula	Age	Sex	Diagnostic method	Comorbidity	Operative method	Therapeutic effect
2	2021	Wang Q et al	Right intermediate bronchus	7yr6mo	F	Bronchoscopy and MRI	None	Surgical excision and ligation	Successful
3	2019	Wu XM et al	Right intermediate bronchus	3yr5mo	F	Bronchoscopy and CT and SPECT	None	Surgical excision and ligation	Successful
4	2018	Chen X et al	Right main bronchus	3yr7mo	F	Bronchoscopy and MRCP	None	Bioadhesive occlusion	Follow-up for 4yr, no recurrence
5	2013	Li K et al	Right main bronchus	27d	F	Bronchoscopy and CT	Extrahepatic biliary atresia	Surgical excision and ligation +Fistula distal-jejunal Roux En-Y anastomosis	Follow-up for 3m, no recurrence
6	2010	Ge Y et al	Right main bronchus	51yr	F	CT	None	Surgical excision and ligation	Successful
7	2021	Bing Z et al	Right main bronchus	2yr	M	Bronchoscopy and CT	None	Surgical excision and ligation	Follow-up for 2yr, no recurrence
8	2021	Thuong Vu et al	Right main bronchus	2m	F	Bronchoscopy and CT	None	Surgical excision and ligation	Successful
9	2019	Li TY et al	Right main bronchus	5d	F	Bronchoscopy and CT and ultrasound	None	Surgical excision and ligation	Follow-up for months, no recurrence

N	Year	Author	Type of fistula	Age	Sex	Diagnosis method	Comorbidity	Operative method	Therapeutic effect
10	2016	Na KJ et Al	Right main bronchus	17yr	M	Bronchus examination and CT and MR imaging	None	Laparoscopic resection and ligation	For no
11	2009	Günlemez et Al	Left main bronchus	9d	F	CT	Extrahepatic biliary atresia	Surgical excision and ligation	For No
12	2004	Hourigan et Al	Right main bronchus	13d	M	MRI	Biliary Dysplasia	Right thoracotomy + Kasia procedure	Su
13	2002	DiFiore et Al	Right main bronchus	< 28 d	M	Intuition intraoperative	Right diaphragmatic hernia	Surgical removal +right diaphragmatic hernia repair	Su
14	1994	Ferkol et Al	Left main bronchus	23d	M	Bronchus examination	Biliary dysplasia	Surgical excision and ligation	Di
15	1993	Gauderer et al	Bilateral main bronchus	3w	F	Bronchoscopy and angiography	None	3 times thoracotomy(fistula clipping et al)+the hepatic left lobe resection	For for yr, sur
			Left main bronchus	1y	F	Bronchoscopy and hepato-biliary scintigraphy	None	Surgical excision and ligation and Roux En-Y anastomosis	For for no
16	1990	Yamaguchi et al	Right main bronchus	32yr	M	Bronchus examination	None	Surgical excision and ligation	Su

N	Year	Author	Type of fistula	Age	Sex	Diagnosis method	Comorbidity	Operative method	Therapeutic effect
17	1988	de Carvalho et al	Right main bronchus	32yr	F	CT	None	Surgical excision and ligation	Follow-up normal
18	1986	Lindahl et Al	Right main Bronchus	15d	F	Bronchus examination	None	Surgical excision and ligation	Successful
19	1985	Chang et al	Right main Bronchus	12h	M	Bronchus examination	None	Surgical excision and ligation	Successful
20	1984	Chan et al	Right main bronchus	4d	F	Not mentioned	Biliary Dysplasia	Surgical excision and ligation	Discharge
21	1976	Kalayoglu et al	Right main bronchus	4d	F	Surgical findings	Esophageal atresia Tracheoesophageal fistula	Surgical excision and ligation	Discharge
22	1971	Sane et al	Right main bronchus	4wk	F	Bronchus examination	None	Surgical excision and ligation	Successful
23	1970	Wagget et Al	Left main Bronchus	3wk	F	Bronchus examination	None	Surgical excision and ligation	Successful
24	1968	Weitzman et Al	Right main Bronchus	2yr9mo	M	Bronchus examination	None	Surgical excision and ligation	Successful
25	1952	Neuhauser et al	Right main bronchus	5mo	F	Bronchus Examination and CT	None	No surgery	Discharge

## 2 Discussion

CBBF is a rare disease with congenital abnormal connection between the hepatic duct and trachea or bronchus. The age of onset and severity of symptoms depend on the diameter of the fistula. Therefore, the symptoms appear at any age from newborn to adults<sup>[9,10,29]</sup>. Typical clinical feature of CBBF is bilious sputum or bile-stained sputum in tracheal intubation. Patients usually have chronic wet coughing, recurrent wheezing, shortness of breath and growth retardation<sup>[12]</sup>. CBBF has usually been misdiagnosed as an

esophagotracheal fistula, gastroesophageal reflux, aspiration pneumonia, tracheoesophageal fistula or high intestinal obstruction<sup>[30,31]</sup>.

In 1952, Neuhauser et al<sup>[29]</sup> reported the first case of CBBF. Up to now, 27 cases have been enrolled in English and Chinese (Table 1). Among them, fourteen (51.8%) cases were diagnosed in the neonatal period, nine (33.3%) were diagnosed in infancy, four (14.8%) were diagnosed in puberty or adulthood. The common manifestations were biliary sputum (24/27, 88.9%), recurrent pneumonia (9/27, 33.3%) and bilious vomiting (7/27, 22.2%). CBBF was more common in female (19/27, 70.3%). The abnormal fistula originates different location around the carina: right main bronchus (21/27, 77.8%), left main bronchus (3/27, 11.1%), right intermediate bronchus (2/27, 7.4%), and bilateral main bronchus (1/27, 3.7%).

The mechanism of CBBF formation is not clearly clarified. However, there are two possible speculated mechanisms. One is considered as the duplication of the upper gastrointestinal tract, which growing between the laryngotrachea and hepatic diverticulum; the other is believed to be the fusion between abnormal bronchial buds and abnormal bile ducts<sup>[20,26]</sup>. The pathological results in our case consistent with the latter pathogenesis.

The detection of bilirubin crystallization in sputum or/and BALF plays crucial role in CBBF diagnosis<sup>[4,5,11-14,29,31]</sup>. Furthermore, abnormal fistula was easily found via bronchoscopy. In this case, the bilirubin detection was positive in the BALF and the location of the fistula connection was confirmed via bronchoscopy and fistula angiography, which provided more comprehensive information and was verified intraoperatively.

Chest CT and airway reconstruction, MRI or isotope examination can find an abnormal fistula from the trachea, through the diaphragm, into the abdominal cavity, and liver lobes communicate with each other<sup>[15]</sup>. Intraoperative management of fistula could base on preoperative isotope examination<sup>[32]</sup>. Liu AH et al<sup>[31]</sup> indicated gas accumulation in the lumen of the right hepatic duct and the gallbladder lumen by hepatobiliary B-ultrasound, which provided clues for clinical diagnosis of BBF.

Patients with CBBF are ineffective to routine treatment and require operation to remove the fistula. If the bile drainage is normal, only thoracic fistula resection can be performed<sup>[33,34]</sup>; there also has reports of resection of thoracic and abdominal fistulas<sup>[13]</sup>. Fistula-jejunostomy Roux-en-Y anastomosis, hilar-jejunostomy, or Cholecystojejunostomy can be performed to fully drain bile so as to avoid fistula recurrence for cases with biliary malformation, such as absence of common bile duct, abnormal bile-intestinal drainage<sup>[14]</sup>.

As surgery has higher cost and more damage, interventional therapy is alternative for CBBF patients without severe biliary malformation. The bronchial occlusion with biological glue has achieved good results in the treatment of adult respiratory diseases<sup>[35,36]</sup>. Tissue glue occlusion via bronchoscopy also have been used in the treatment of adult secondary bronchobiliary fistulas<sup>[36-38]</sup>. Chen X et al<sup>[7]</sup> successfully cured the pediatric patient with congenital brachobiliary fistula for the first time via bronchoscopy. The interventional treatment via bronchoscopy in patients with bronchobiliary fistula requires respiratory intervention doctors to achieve further breakthroughs in future.

Combined this case and literature review, twenty-three (85.2%) patients recovered after operation, four (14.8%) patients died from severe comorbidities (biliary dysplasia (n=1), biliary atresia(n=1), congenital diaphragmatic hernia(n=1), esophageal atresia and/or tracheoesophageal fistula (n=1)). Two cases had complications (pneumothorax (n=1), septicemia(n=1)). one case with no surgery. CBBF patients with delayed or no operation, severe biliary malformation, or severe postoperative complications have poor prognosis<sup>[17,23,24,28]</sup>.

### 3 Conclusion

In conclusion, CBBF should be suspected in infants with bilious sputum. Besides, bronchoscopy plays crucial role in preoperative evaluation and postoperative follow-up. With early diagnosis and surgery, the prognosis is good for CBBF patients without severe biliary malformation and/or severe postoperative complications.



## Authors' contributions

Conception and design: GL Z, ZX L; Administrative support: ZX L, J L; Bronchoscopy and bronchoscopic figures: CJ W, GL Z; Provision of study materials or patients: ZL W, XY T, YY L, QY L, XJ X; Imaging and pathological figures: H D, J Z; Manuscript writing: GL Z, ZX L; Final approval of manuscript: All authors

## Funding

No founding sources.

## Availability of data and materials

not applicable. **Competing interests**

No competing interests for all authors.

## Author details

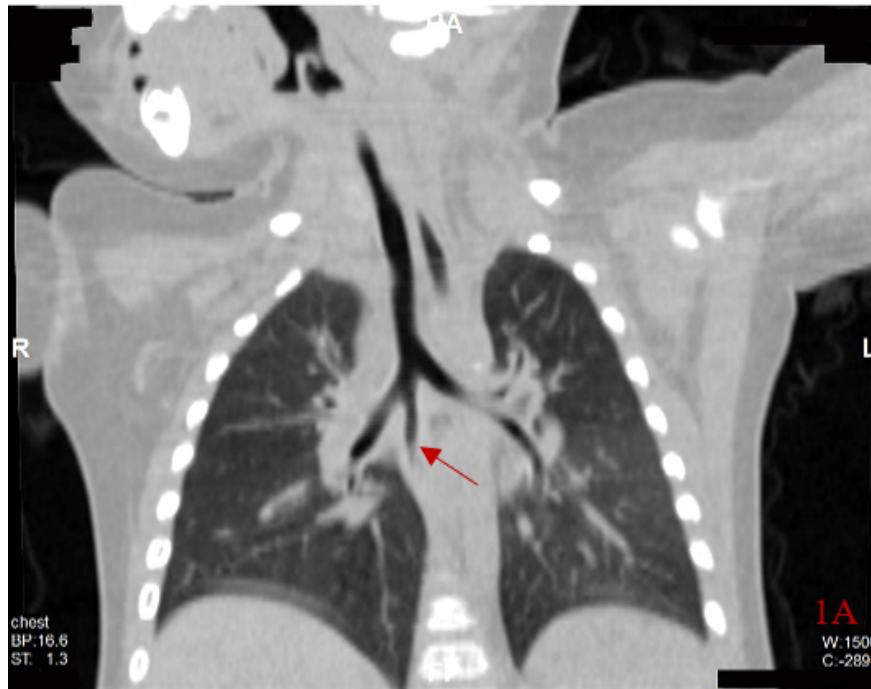
<sup>1</sup> Department of Respiratory Medicine, Children's Hospital of Chongqing Medical University, National Clinical Research Center for Child Health and Disorders, Ministry of Education Key Laboratory of Child Development and Disorders, Chongqing Key Laboratory of Pediatrics, Chongqing 400010, China; <sup>2</sup> Department of Radiology, Children's Hospital of Chongqing Medical University; <sup>3</sup> Department of Pathology, Children's Hospital of Chongqing Medical University

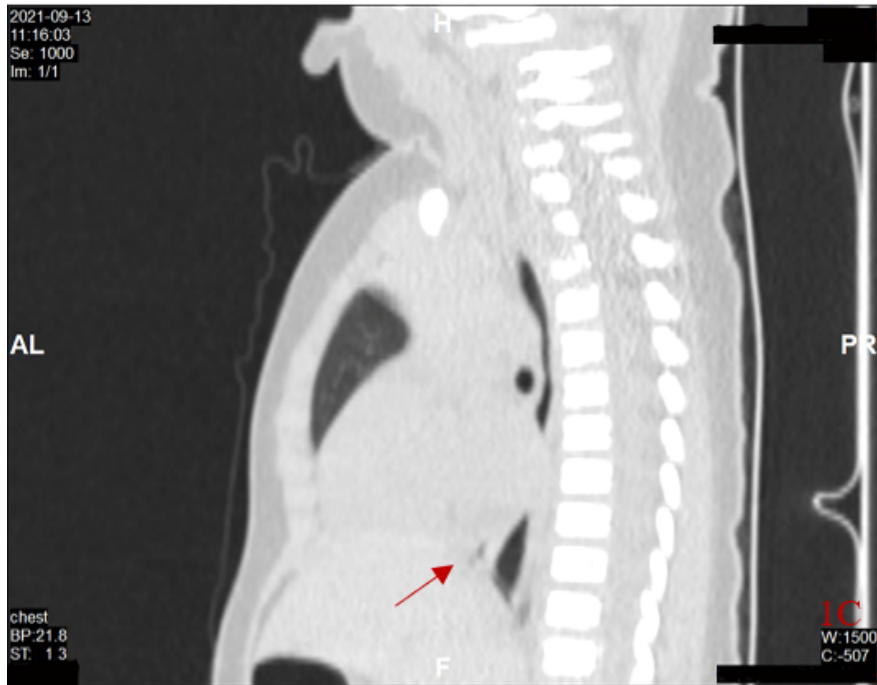
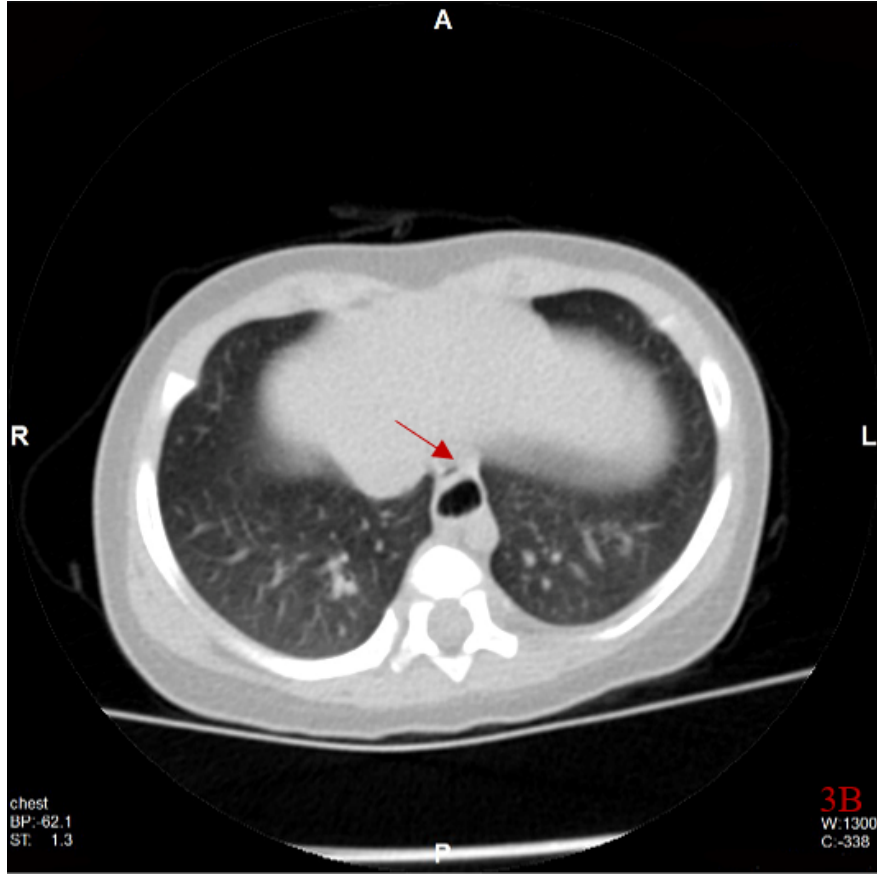
## References

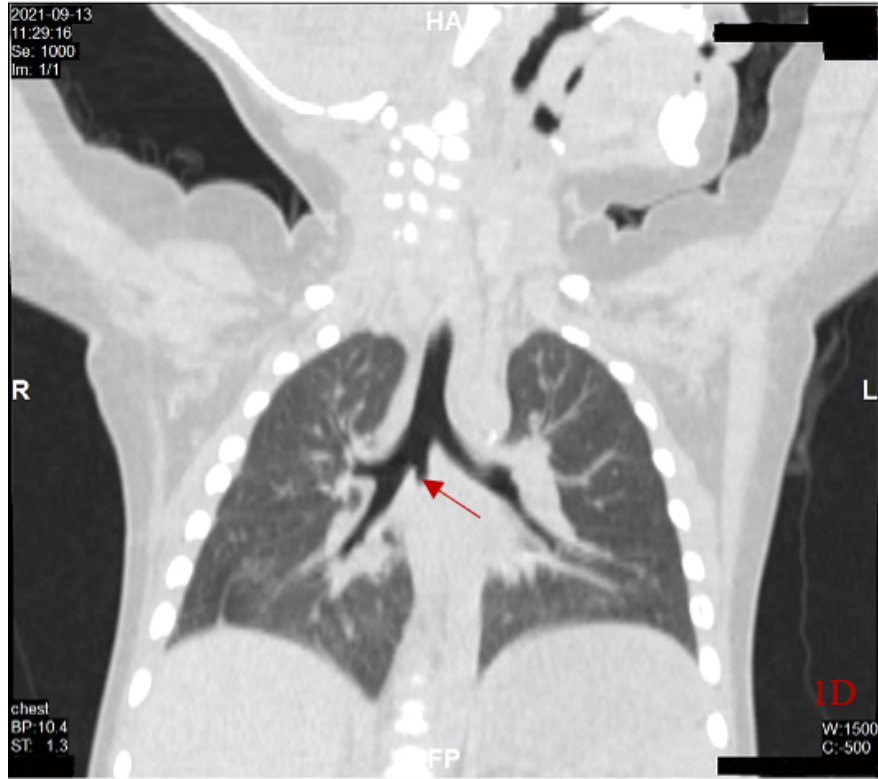
1. Cheng AC, Chen HW, Chen PJ, Huang TY, Lin JC. Bronchobiliary Fistula. *Intern Emerg Med.* 2021; 16: 1093-1094. doi: 10.1007/s11739-020-02572-0.
2. Huang ZM, Zuo MX, Gu YK, Lai CX, Pan QX, Yi XC, et al. Bronchobiliary fistula after ablation of hepatocellular carcinoma adjacent to the diaphragm: Case report and literature review. *Thorac Cancer.* 2020; 11(5): 1233-1238. doi: 10.1111/1759-7714.13380.
3. Zhang N, Chen Y, Tang L, Zhou D, Hou T, et al. Diagnosis of bronchobiliary fistula by bilirubin crystallization in the alveolar lavage fluid case reports and literature review. *Ann Palliat Med,* 2021; 10(6): 7121-7125. doi: 10.21037/amp-21-1040.
4. Meng EY, Xia L, Shang HL, Dong HF, Shang LH, Xu FL. A Case of neonatal congenital broncho-biliary fistula with biliary atresia and literature review. *HeNan Medical Research.* 2021; 30(6): 4842-4847. doi: 10.3969/j.issn. 1004-437X.2021.26.010.
5. Wang Q, Chen M, Jin R, Sun YF, Xu H, Cheng X, et al. Case report of congenital broncho-bileduct fistula. *Clin J Appl Clin Pediatr.* 2021; 36(1): 67-69. doi: 10.3760/cma.j.cn101070-20191022-01027.
6. Wu XM, Chen YJ, Pang WB, Huang JS. A case report of congenital bronchobiliary fistula and miss diagnosis[J]. *J Clin Ped Surg.* 2019; 18(5): 429-431. doi: 10.3969/j.issn.1671-6353.2019.05.018.
7. Chen X, Yan YQ, Deng WH, Ren JH, Shu JH, Wu YB. Congenital tracheobiliary fistula treated with biological glue plugging under bronchoscopic guidance: a case report and literature review. *Clin J Appl Clin Pediatr.* 2018; 33(11): 839-841. doi: 10.3760/cma.j.issn.2095-428X.2018.11.011.
8. Li K, Zheng S, Xiao XM, Cao Y, Wang LS. Neonatal congenital broncho-biliary fistula- a case report and literature review. *Clin J Pediatr Surg.* 2013; 34(6):447-449. doi: 10.3760/cma.j.issn.0253-3006.2013.06.012.
9. Ge Y, Wu JL, Zhang TT, Tan QW, Zheng B. A case of ongenital biliary bronchial fistula. 2010; 44(5): 556. doi: 10.3760/cma.j.issn.1005-1201.2010.05.030
10. Bing Z, Chen R, Xing P, et al. Congenital Bronchobiliary Fistula A Case Report and Literature Review[J]. *Front Pediatr,* 2021, 9: 686827.
11. Thuong Vu L, Minh Duc N, Tra My TT, Tan Lien Bang M, Tuan Linh L, Quynh Huong T. Congenital bronchobiliary fistula a case report and literature review. *Respirol Case Rep.* 2021; 9(4): e00731. doi: 10.1002/rcr2.731.

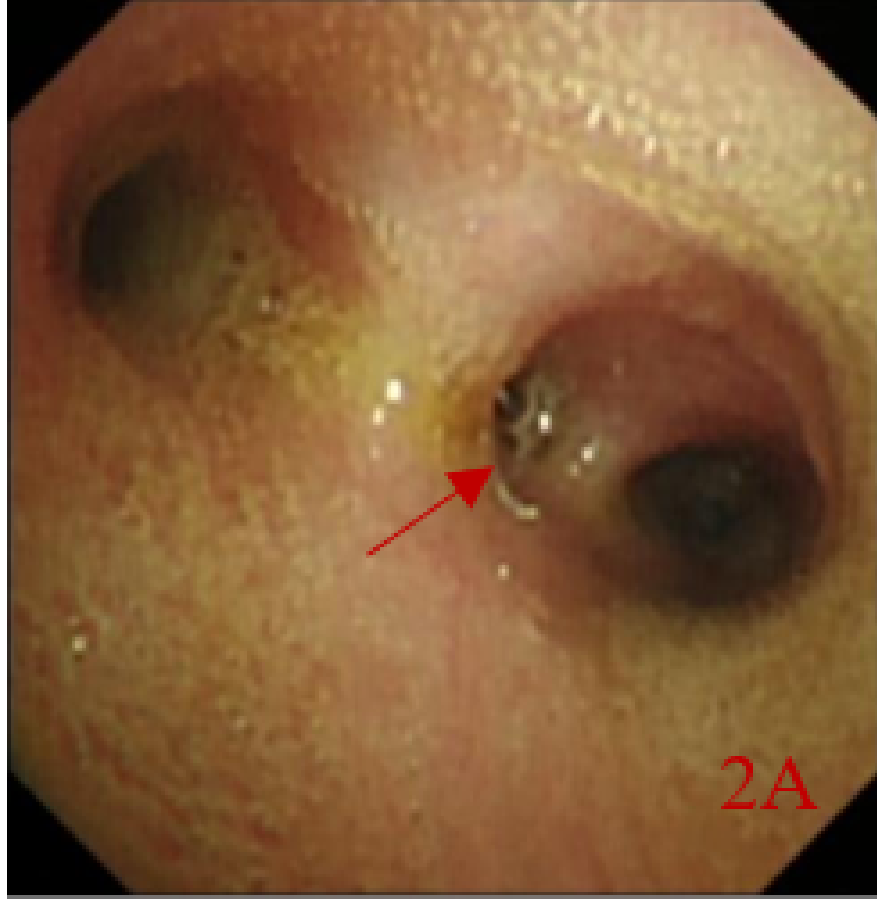
12. Li TY, Zhang ZB. Congenital bronchobiliary fistula A case report and review of the literature. *World J Clin Cases*. 2019; 7(7):881-890. doi: 10.12998/wjcc.v7.i7.881.
13. Na KJ, Jung JC, Hwang Y, Lee HJ, Park IK, Kang CH, et al. Minimally Invasive Surgical Repair for Congenital Bronchobiliary Fistula in an Adult. *Ann Thorac Surg*. 2016; 101: 1584-1587. doi: 10.1016/j.athoracsur.2015.05.126.
14. Günlemez A, Tugay M, Elemen L, Türker G, Gürcan NI, Demir H, et al. Surgical experience in a baby with congenital broncho-biliary fistula. *Ann Thorac Surg*. 2009; 87: 318-320. doi: : 10.1016/j.athoracsur.2008.06.028.
15. Hourigan JS, Carr MG, Burton EM, Ledbetter JC. Congenital bronchobiliary fistula: MRI appearance. *Pediatr Radiol*. 2004; 34: 348-350. doi: 10.1007/s00247-003-1091-6.
16. DiFiore JW, Alexander F. Congenital bronchobiliary fistula in association with right-sided congenital diaphragmatic hernia. *J Pediatr Surg*. 2002; 37: 1208-1209. doi: 10.1053/jpsu.2002.34477.
17. Ferkol T, McDowell KM, Gauderer MW, Alpert SE. Sinopulmonary manifestations of congenital bronchobiliary fistula. *Clin Pediatr (Phila)*. 1994; 33: 181-184. doi: 10.1177/000992289403300314.
18. Gauderer MW, Oiticica C, Bishop HC. Congenital bronchobiliary fistula: management of the involved hepatic segment. *J Pediatr Surg*. 1993; 28: 452-455. doi: 10.1016/0022-3468(93)90247-i.
19. Yamaguchi M, Kanamori K, Fujimura M, Watanabe Y, Matsuda T. Congenital bronchobiliary fistula in adults. *South Med J*. 1990; 83: 851-852. doi: 10.1097/00007611-199007000-00032.
20. de Carvalho CR, Barbas CS, Guarneri RM, de Campos JR, Filomeno LT, Saldiva PH, et al. Congenital bronchobiliary fistula: first case in an adult. *Thorax*. 1988; 43: 792-793. doi: 10.1136/thx.43.10.792.
21. Lindahl H, Nyman R. Congenital bronchobiliary fistula successfully treated at the age of three days. *J Pediatr Surg*. 1986; 21: 734-735. doi: 10.1016/s0022-3468(86)80399-2.
22. Chang CC, Giulian BB. Congenital bronchobiliary fistula. *Radiology*. 1985; 156: 82. doi: 10.1148/radiology.156.1.4001424.
23. Chan YT, Ng WD, Mak WP, Kwong ML, Chow CB. Congenital bronchobiliary fistula associated with biliary atresia. *Br J Surg*. 1984; 71: 240-241. doi: 10.1002/bjs.1800710329.
24. Kalayoglu M, Olcay I. Congenital bronchobiliary fistula associated with esophageal atresia and tracheoesophageal fistula. *J Pediatr Surg*. 1976; 11: 463-464. doi: 10.1016/s0022-3468(76)80205-9.
25. Sane SM, Sieber WK, Girdany BR. Congenital bronchobiliary fistula. *Surgery*. 1971; 69: 599-608. doi: 10.1016/s0022-3468(71)80034-9.
26. Wagget J, Stool S, Bishop HC, Kurtz MB. Congenital bronchobiliary fistula. *J Pediatr Surg*. 1970; 5: 566-569. doi: 10.1016/0022-3468(70)90012-6
27. Weitzman JJ, Cohen SR, Woods LO, Chadwick DL. Congenital bronchobiliary fistula. *J Pediatr*. 1968; 73: 329-334. doi: 10.1016/S0022-3476(68)80108-8.
28. Neuhauser EB, Elkin M, Landing B. Congenital direct communication between biliary system and respiratory tract. *AMA Am J Dis Child*. 1952; 83: 654-659. doi: 10.1001/archpedi.1952.02040090100012.
29. Pathak S, Jethi S, Saoji R. Isolated congenital tracheobiliary fistula. *Indian Pediatr*. 2018;55: 995-996.
30. Wilson NA, Douglas ZH, Briden K, Witt R, Lodhi HS, Cole FS, et al. Video-assisted Thoracoscopic Resection of a Congenital Tracheobiliary Fistula in a Neonate Technical Report and Review of the Literature. *Surg Laparo Endo Per*. 2021; 32(2): 266-271. doi: 10.1097/SLE.0000000000001000.
31. Liu AH, Zhao SY, Wang W. Congenital biliary bronchial fistula A case report and literature review. *Chinese Remedies & Clinics*. 2018; 18(11): 2015-2017. doi: 10.11655/zgywylc2018.11.069
32. Yuan L, Yang H, Yang J, Ma D. Congenital tracheobiliary fistula shown on 99mTc-EHIDA hepatobiliary scintigraphy. *Clin Nucl Med*. 2016; 41(2): 164-166. doi: 10.1097/RLU.0000000000000989.
33. Kim JS, Suh JH, Park CB, Yooh JS. Congenital tracheobiliary fistula in an adolescent patient[J]. *Ann Thorac Surg*. 2015; 99(1):328-331. doi: 10.1016/j.athoracsur.2013.12.062.
34. Pérez CG, Reusmann A. Congenital broncho-biliary fistula: a case report[J]. *Arch Argent Pediatr*, 2016; 114(5):e350-e353. doi: 10.5546/aap.2016.e350.
35. Kondo N, Hashimoto M, Takuwa T, Matsumoto S, Okumura Y, Hasegawa S. Treatment of bronchial fistula after extrapleural pneumonectomy using flexible bronchoscopy with the administration of OK432, fibroblast growth factor basic and fibrin glue sealant. *Gen Thorac Cardiovasc Surg*. 2020; 68(12): 1562-

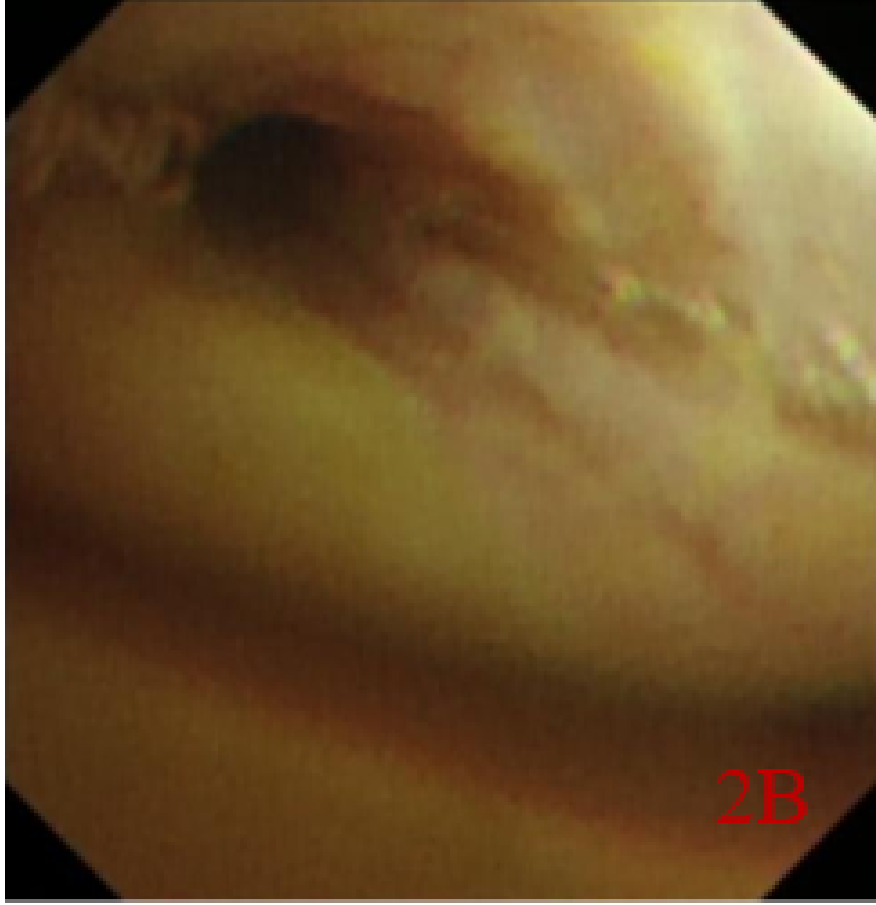
1564. doi: 10.1007/s11748-020-01349-8.
36. Mukkada RJ, Antony R, Francis JV, Chettupuzha AP, Augustine P, Venugopal B, et al. Bronchobiliary fistula treated successfully with endoscopic microcoils and glue[J]. *Ann Thorac Surg*, 2014; 98(2): e33-e34. doi: 10.1016/j.athoracsur.2014.04.052.
37. Yu Lee-Mateus A, Garcia-Saucedo JC, Abia-Trujillo D, Kroner PT, Gomez V, Fernandez-Bussy S. Bronchobiliary Fistula Management With Bronchoscopic Occlusive Stenting and Fibrin Glue Instillation.. *J Bronchology Interv Pulmonol*. 2022; 29(3):e49-e51. doi: 10.1097/LBR.0000000000000812.
38. Lee S, Lee JH, Kim HB, Lee JJ. Percutaneous Bronchial Embolization to Treat Intractable Bronchobiliary Fistula. *Cardiovasc Inter Rad*. 2019; 42(5): 784-786. doi: 10.1007/s00270-019-02166-0.

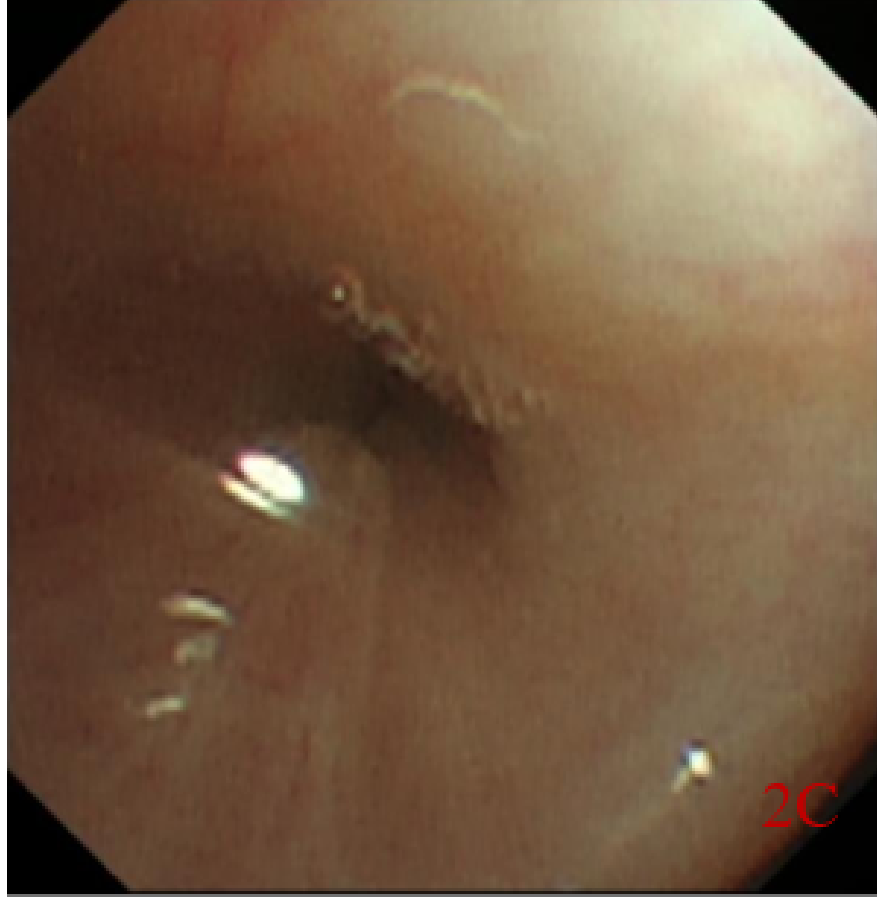




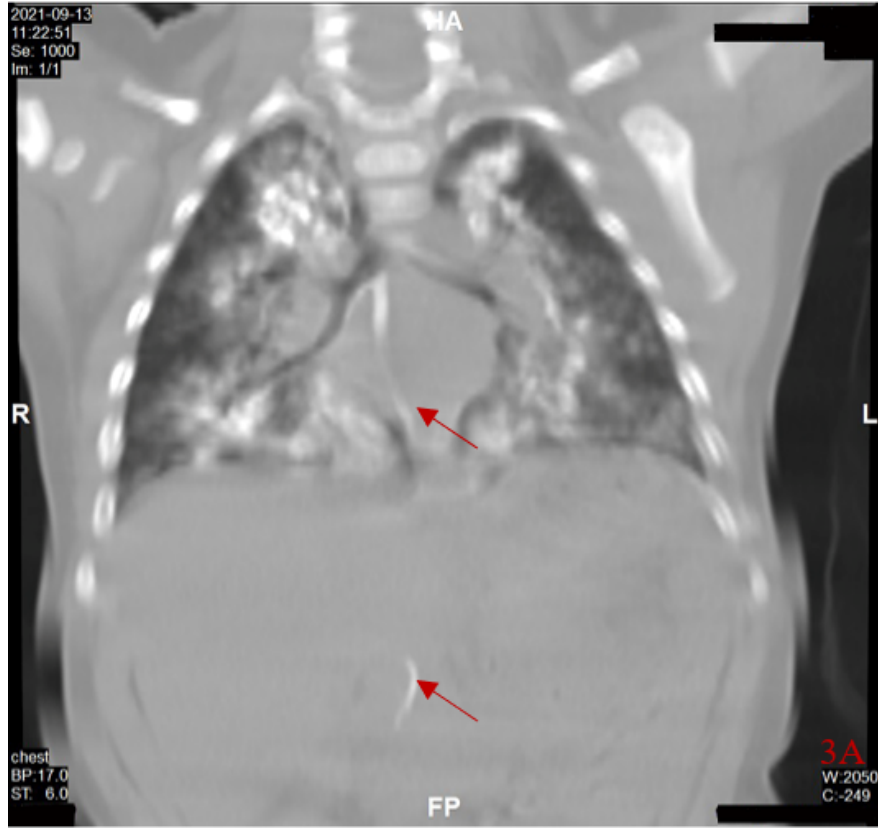


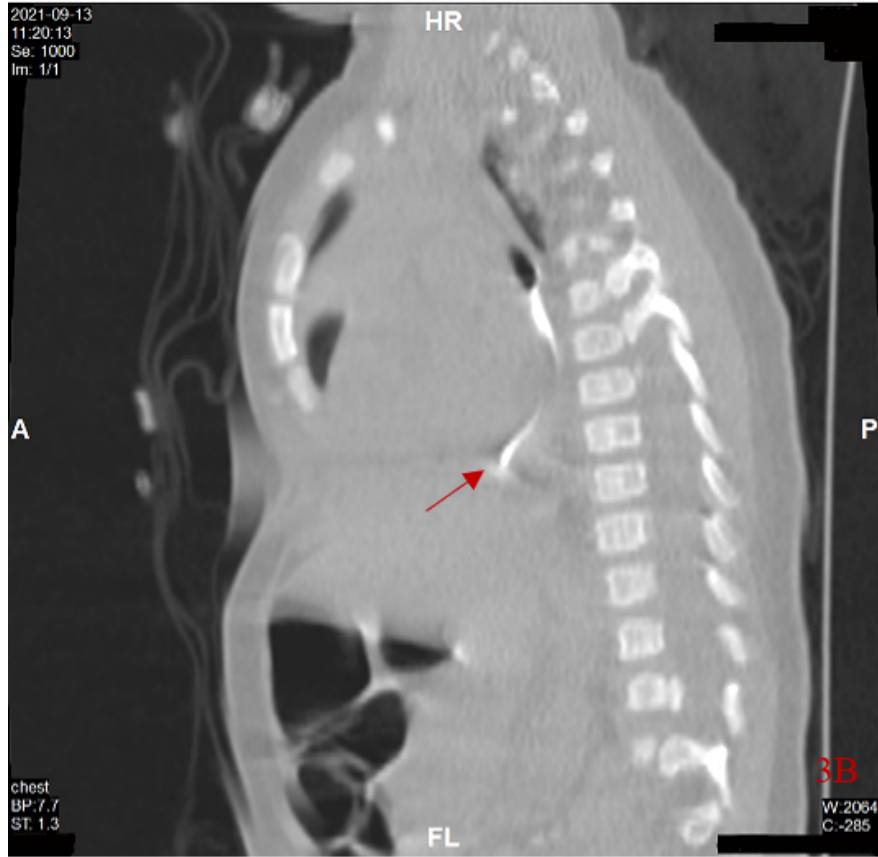


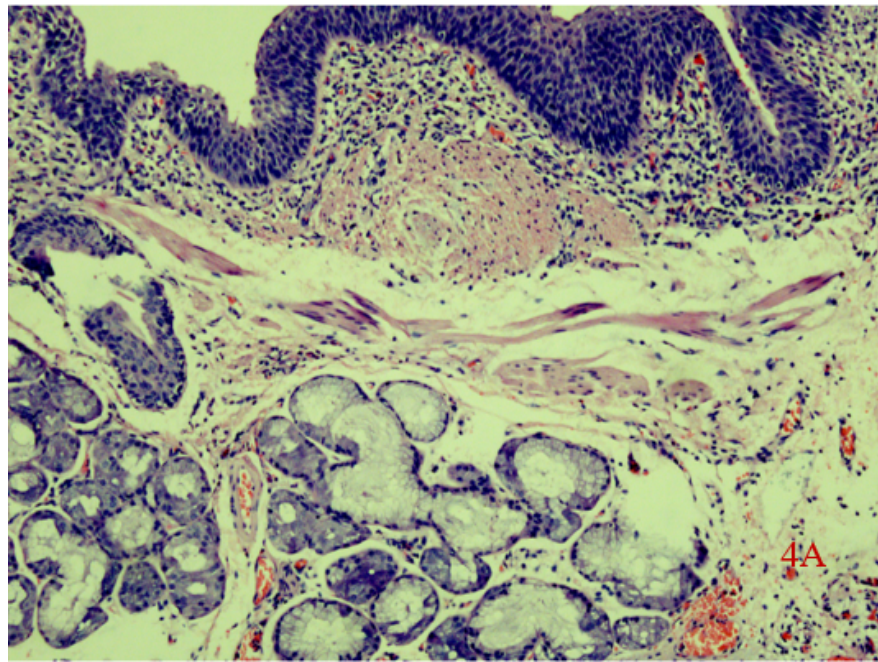
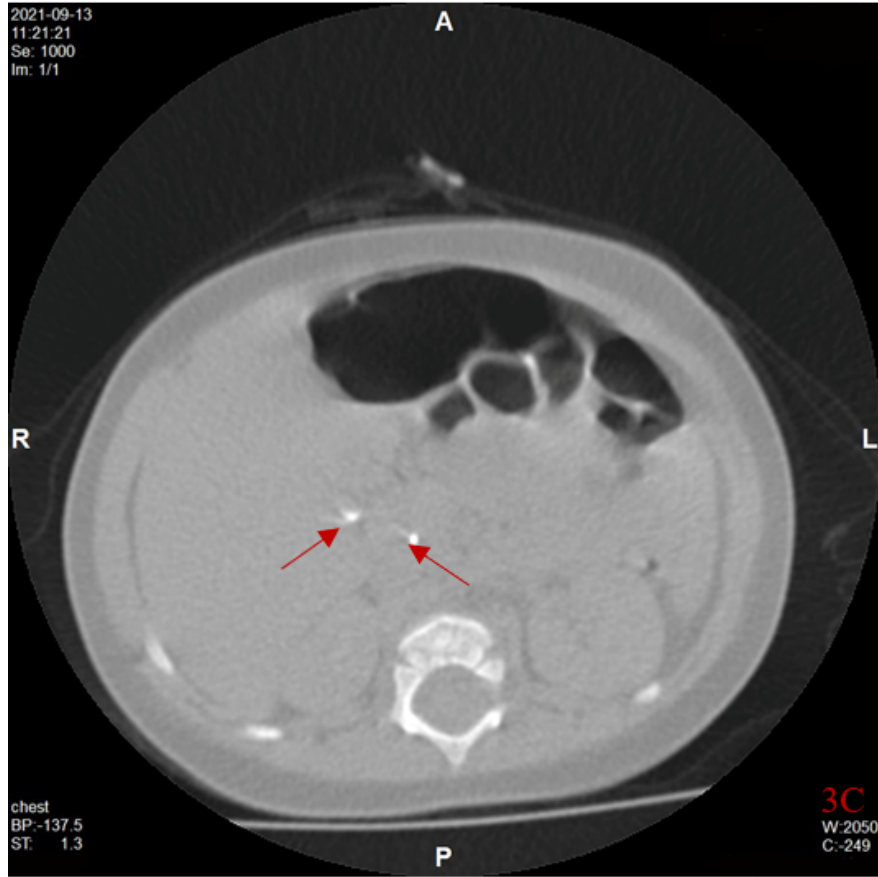


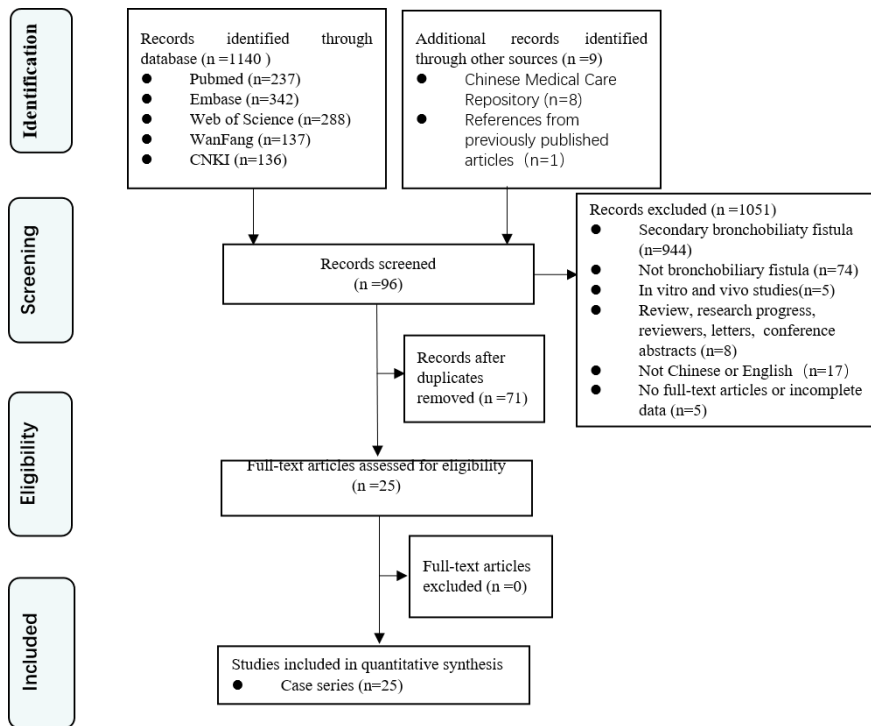
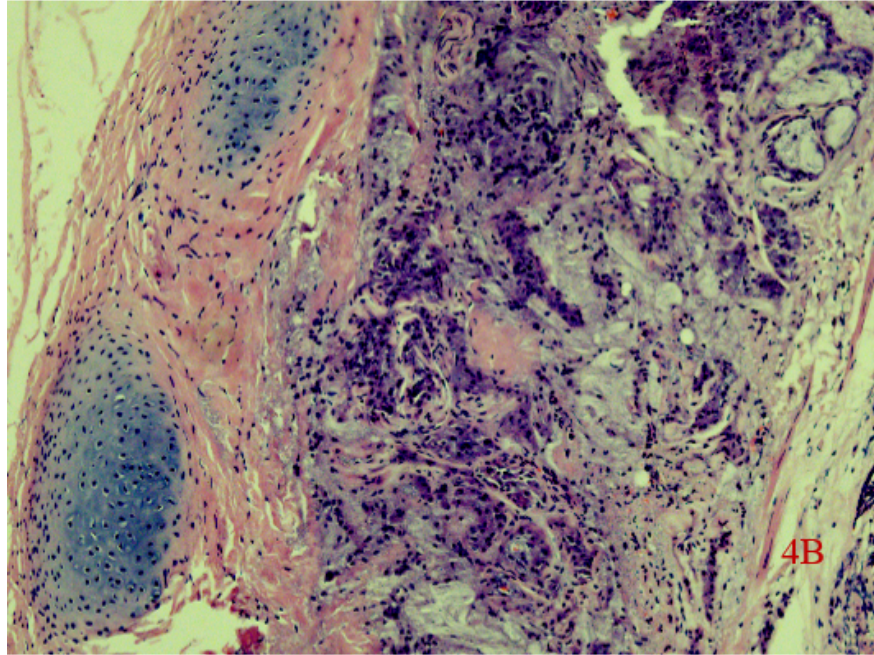












### Hosted file

table 1.docx available at <https://authorea.com/users/588413/articles/625624-diagnosis-of-congenital-bronchobiliary-fistula-in-children-by-bilirubin-crystallization-in-the-bronchoalveolar-lavage-fluid-a-case-report-and-literature-review>