

Dislocation of the hip joint, papillary thyroid carcinoma and diabetes and their impact on Turner syndrome: a case report

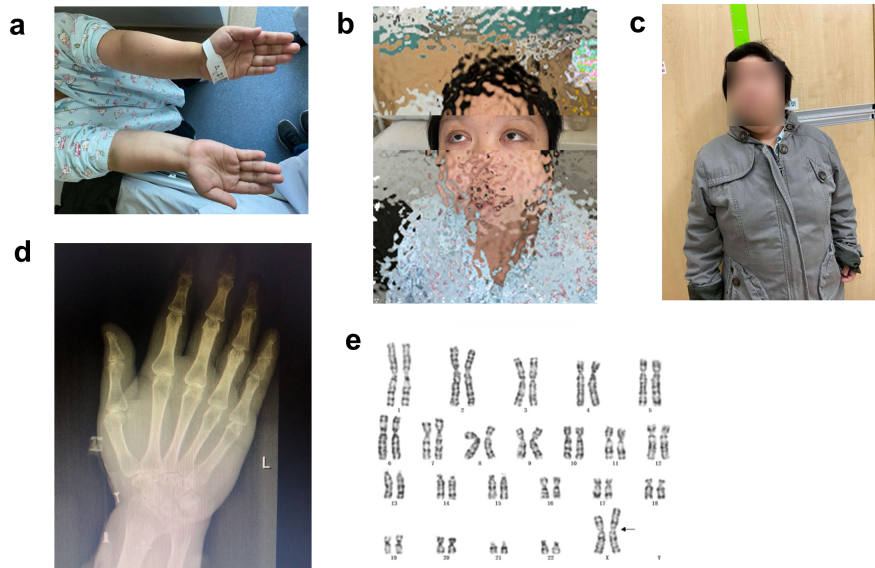
Jinxin Huang¹, Xiaohong Jiang¹, and Long Wang¹

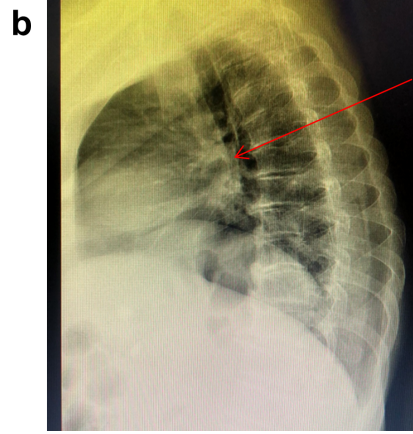
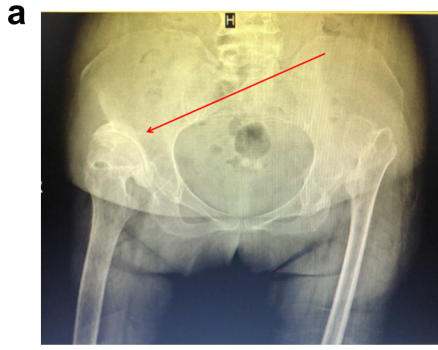
¹Third Affiliated Hospital of Soochow University

December 23, 2022

Abstract

We reported a case of Turner syndrome combined with diabetes, double hip dislocation (congenital), osteoporosis, Papillary thyroid carcinoma, and hypertension. The patient was a 38-year-old woman who was admitted to the hospital for elevated blood sugar.





Dislocation of the hip joint, papillary thyroid carcinoma and diabetes and their impact on Turner syndrome: a case report

Jinxin Huang, Xiaohong Jiang, Long Wang *

The Third Affiliated Hospital of Soochow University, 185 Zhuqian Street, Changzhou City,
213000, P.R. China

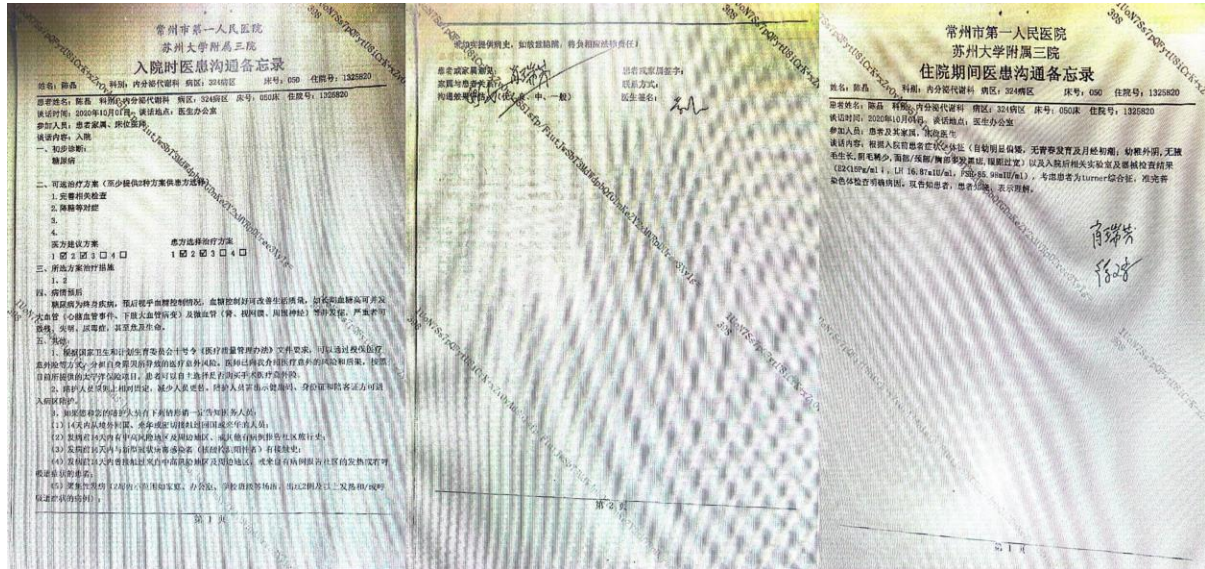
*Corresponding author: Professor Long Wang, The Third Affiliated Hospital of Suzhou
University, 185 Zhuqian Street, Changzhou City, 213000, P.R. China

Email: 305783449@163.com

Tel: 86-051968870141

[Patient consent statement]

Written informed consent was obtained from the patient to publish this report in accordance with the journal's patient consent policy.



[Key word] Turner syndrome; diabetes; congenital hip dislocation; osteoporosis; thyroid papillary carcinoma

[Abstract]

We found a rare clinical manifestation of Turner syndrome: dislocation of hip joint with diabetes. The patient had growth retardation, blood pressure 146/92mmhg, bone density:<2.5, the chromosome karyotype 46,X,i(X)(q10)[45]/45,X[15], FBG 12mmol/l, 2hBG 17.4mmol/l, HbA1c 10.8%, follicle-stimulating hormone (FSH) 85.98uIU/ml, luteinizing hormone (LH) 16.87uIU/ml, estrogen (E2) < 15pg/ml, low C-P level, dislocation of both hip joints (congenital), and short femoral neck, and was diagnosed as Turner syndrome complicated with diabetes, dislocation of hip joint, osteoporosis, hypertension and thyroid papillary carcinoma. So if a patient is found to have a congenital dislocation of the hip joint at an early age, the possibility of Turner syndrome should be considered for early identification and diagnosis, thyroid papillary carcinoma should be screened so as not to delay the disease.

[Introduction] We report a young woman had rare clinical manifestation of Turner syndrome: dislocation of hip joint, osteoporosis, hypertension with diabetes and thyroid papillary carcinoma. To the best of our knowledge, this is the first well-documented case of this association.

[Case presentation] A 38-year-old woman who was admitted to the hospital for elevated blood sugar during the previous month and nausea and vomiting for 3 days. The patient was born a first child, was full-term, her weight was unknown, and her mother had no medication history during pregnancy. After birth, her height was obviously shorter than her peers from childhood, with no attention, no rapid height growth during adolescence, no breast or external genital development, and no menstrual cycle. The decline in intelligence was manifested as an inability to count, and the sense of understanding and positioning was normal. She had no

brothers or sisters. Her parents were not close relatives, and she was physically fit. The patient came to our hospital on October 1, 2020. She was found to have high blood sugar before the physical examination, her fasting plasma glucose was 12.04 mmol/l, she had no obvious dry mouth, she did not consume fluids, she did not urinate, and she lost 6 kg. After admission to the hospital, the patient's fasting plasma glucose was 11 mmol/l, postprandial blood glucose was 14 mmol/l, urinary ketone body (+), and glycoalbumin was 10.2%, and she was diagnosed with diabetes. She had hypertension for 20 years and used nifedipine to control her blood pressure. Physical examination revealed a height of 135 cm; a weight of 54 kg; body fat, multiple nevi on the face, neck, and chest; an excessively wide eye distance; and elbow turn [**Fig 1**]. Her skin was delicate, and her hair was thin. Her fingers were not thick, and she had no special facial features, no abdominal purpura, mammary gland development stage 2, no trigger galactorrhea, childish vulva, pubic hair P2-3 stage. The patient exhibited a Trendelenburg gait.

The laboratory examinations were as follows: chromosome karyotype 46,X,i(X)(q10)[45]/45,X[15], follicle-stimulating hormone (FSH) 85.98 uIU/ml, luteinizing hormone (LH) 16.87 uIU/ml, estrogen (E2) < 15 pg/ml, prolactin (PRL) < 15 pg/ml, testosterone (T) 0.41 ng/ml, free T3 (FT3) 4.97 pmol/l, free T4 (FT4) 23.85 pmol/l, thyroid-stimulating hormone (TSH) 2.17 uIU/ml, thyroglobulin (TGAB) 15.80 ng/ml, TPOAb < 5 Iu/ml, PTH 42.1 Pg/ml, cortisol (8 am, 16 pm 8.17 µg/dl, 7.36 µg/dl, ACTH (8 am, 16 pm 8.4 pg/ml, 5.56 pg/ml), FPG 12.04 mmol/l, 2hPG 14 mmol/l, HbA1C 10.8%, urinary ketones(+), C-P release experiments: FC-P 332.5 pmol/l, 0.5 hC-P 697.5 pmol/l, 1hC-P 694.7 pmol/l, 2hC-P 818.3 pmol/l, and 3hC-P 790.6 pmol/l. The gynecological ultrasound findings were as follows: childish uterus, and the two sides of the ovaries were not clear. The cardiac ultrasound findings were as follows: The aorta was incomplete. The chest lumbar

vertebrae were positive: multiple wedge deformation was exhibited. Hip X-rays showed double hip dislocation (congenital) and short neck [Fig 2]. Bone density indicated osteoporosis. At the same time, we found that the patient had left lobe thyroid nodules, 1.7*1.2cm in left lobe, which was BRAFV600E mutation-positive and was diagnosed as left lobe thyroid papillary carcinoma with left central lymph node metastasis after partial left lobe thyroidectomy.

The diagnosis was as follows: Turner syndrome combined with diabetes, double hip dislocation (congenital), osteoporosis, Papillary thyroid carcinoma, and hypertension. Treatment: Insulin 4 IU premeal injections, sitagliptin 100 mg qd, FPG control at 5.7-6.4 mmol/l, 2hPG control at 6.8-9.3 mmol/l, nifedipine 30 mg// qd, and blood pressure maintained at 120-140/80-90 mmHg. Vitamin D3 calcium carbonate 1 tablet qd, vitamin D 800iu qd. Levothyroxine sodium tablets 150ug qd. Sex hormone replacement therapy: estradiol valerate tablets 0.25 mg/qd, progestogen not added at this time.

[Discussion] Approximately half of TS cases are X monotypes (45,XO), 20% to 30% are chimed (45,XO/46,XX), and the rest are X chromosomal structural abnormalities. Tissue-specific gene expression analysis of the DEGs revealed that the system with the most highly enriched tissue-specific gene expression was the hematologic/immune system, followed by the skin/skeletal muscle and neurologic systems. IGFBP2 is related to skeletal abnormalities^[1]. This patient had a chimed type. There are currently more reports of Turner syndrome combined with diabetes, Hashimoto's thyroiditis, hypothyroidism, and hypertension. However, there were few reports of complicated papillary thyroid carcinoma, M. Papanikolaou^[2] found Mosaic Turner syndrome, papillary thyroid carcinoma, associated

with BRAFV600E, which was similar to what we found. In this case, a series of clinical abnormalities, such as smallness, ovarian under-development, diabetes, hypertension, intellectual impairment, aortic insufficiency, and osteoporosis, can be explained by Turner syndrome. Skeletal system anomalies are extensive in TS patients as well. Turner syndrome patients often show malformations in the sternum, and some patients have elbow flipping, a short fourth metacarpal, bent toes, femoral and tibial exogenous warts, phalanx dysplasia, occasional genu valgus and scoliosis. Suna Kilinc^[3] found that the prevalence of skeletal system anomalies was half in their study, and scoliosis was the most common pathology. However, Turner syndrome combined with hip dislocation is rare and less reported. Infants with TS have an increased risk of congenital hip dislocation, but joint malformation could also occur. Syndromic dysplasia also exists in association with different pathologies, such as Down's syndrome and neurogenic, renal or cardiovascular abnormalities^[4]. When Daniela Duca discovered Coxoauricular syndrome in 1981, one of the women had Turner syndrome and congenital dislocation of the hip. If laxity of the femoral head is present after birth, neonatal hip instability (NHI) can be diagnosed. This instability is usually present for the first few weeks of life. Persistent joint instability can be caused by disordered reflex contraction in soft tissues, which under physiological circumstances, fixates the hip joint until six months of age. After sixth months of age, spontaneous resolution is very unlikely^[5]. If the best time for treatment has already passed when hip dislocation is found, hip dislocation cannot be not treated in a timely manner, affecting the development of the hips and resulting in short stature. Therefore, in young children born with combined hip dislocation, Turner syndrome needs to be identified at an early age and should be given early and clear diagnosis and initial

treatment to avoid growth retardation and gonadal dysplasia. Thyroid tumors should also be screened during growth.

[Conflict of interests]

The authors declare that there is no conflict of interest.

[Figure legends]

Fig1. (a)Mild elbow valgus, (b)epicanthus, (c)pygmyism, (d)the epiphysis is closed, (e)The chromosomekaryotype46,X,i(X)(q10)[45]/45,X[15].

Fig 2. (a)Double dislocation of hip joint, short neck of femur. (b)Thoracolumbar anterior and lateral position: multiple wedge changes.

[References]

- [1] Wang H, Zhu H, Zhu W, Xu Y, Wang N, Han B, et al. Bioinformatic Analysis Identifies Potential Key Genes in the Pathogenesis of Turner Syndrome. *Frontiers in Endocrinology* 2020;11.
- [2] Papanikolaou M, Chohan T, Millington GWM. Malignant melanoma, papillary thyroid carcinoma and Erdheim-Chester disease, associated with both BRAF(V600E) and mosaic Turner syndrome. *Clin Exp Dermatol* 2020;45:512-514.
- [3] Kilinc S, Yildiz M, Guven A. Associated clinical abnormalities among patients with Turner syndrome. *North Clin Istanbul* 2020;7:226-230.
- [4] Harsanyi S, Zamborsky R, Krajciova L, Kokavec M, Danisovic L. Developmental Dysplasia of the Hip: A Review of Etiopathogenesis, Risk Factors, and Genetic Aspects. *Medicina (Kaunas, Lithuania)* 2020;56.
- [5] Kotlarsky P, Haber R, Bialik V, Eidelman M. Developmental dysplasia of the hip: What has changed in the last 20 years? *World journal of orthopedics* 2015;6:886-901.