

Extracerebral anaplastic meningioma

Guido Carillio¹, Anna Maria Lavecchia¹, and Demetrio Misuraca¹

¹Pugliese-Ciaccio Hospital

November 22, 2022

Abstract

Anaplastic meningioma rarely involves organs outside the brain. In our case a patient with cerebral meningioma developed lung metastases after 19 years from the initial appearance. This unusual tumor presentation could make complex the diagnosis.

Clinical Case Reports – Case Image

Extracerebral anaplastic meningioma

Guido Carillio, MD¹ (guidocarillio@gmail.com)

Anna Maria Lavecchia, MD² (amlavecchia@libero.it)

Demetrio Misuraca, MD¹ (misuracademetrio@gmail.com)

¹Department of Oncohematology

Pugliese-Ciaccio Hospital

viale Pio X

88100 Catanzaro – ITALY

Tel.: 0039-0961-883756

Fax: 0039-0961-883467

²Division of Anatomical Pathology

Pugliese-Ciaccio Hospital

Viale Pio X

88100 Catanzaro – ITALY

Tel.: 0039-0961-883328

CORRESPONDENCE TO:

Dr. Guido Carillio

via Enotria 81

89122 Reggio Calabria

ITALY

Email:guidocarillio@gmail.com

Consent statement

Written informed consent was obtained from a patient's next of kin to publish this report in accordance with the journal's patient consent policy.

Abstract

Anaplastic meningioma rarely involves organs outside the brain. In our case a patient with cerebral meningioma developed lung metastases after 19 years from the initial appearance. This unusual tumor presentation could make complex the diagnosis.

Keywords : extracerebral meningioma; lung metastases.

Case report

A 69-year-old man with history of relapsing encephalic meningioma treated since 1994 to 2008 with three surgical interventions and brain radiotherapy underwent a left hemicolectomy in June 2015 for colon carcinoma, AJCC staging pT3 N2 (5 of 23 positive nodes). Tumor markers were negative and basal CT scan showed a suspected nodule in the left lower lung lobe. Chemoimmunotherapy with FOLFIRI and panitumumab was administered, yielding stable disease. A resection of the known lung nodule was performed in June 2016 and allowed to diagnose a rare form of extracerebral rhabdoid meningioma of grade 3 as WHO classification. In December 2019 patient reported severe pain in the left chest wall. PET/CT scan revealed two metabolic active nodules beside the fourth and seventh ribs (Figure 1). Histological and immunohistochemical (H&E, EMA, and Ki67 staining) diagnosis of thoracic anaplastic meningioma was confirmed by a new biopsy (Figure 2). Patient was treated with VMAT radiotherapy in the both nodules and oral chemotherapy with temozolomide, but he experienced a rapid and impressive intrathoracic disease progression (CT scan in Figure 3). An empiric second line antiangiogenic therapy with intravenous bevacizumab at 10 mg/Kg every two weeks led to stable disease lasting 19 months, until the lung mass caused pressure against the left cardiac ventricle, ejection fraction decrease and final heart failure.

Word count: 215

Figure 1

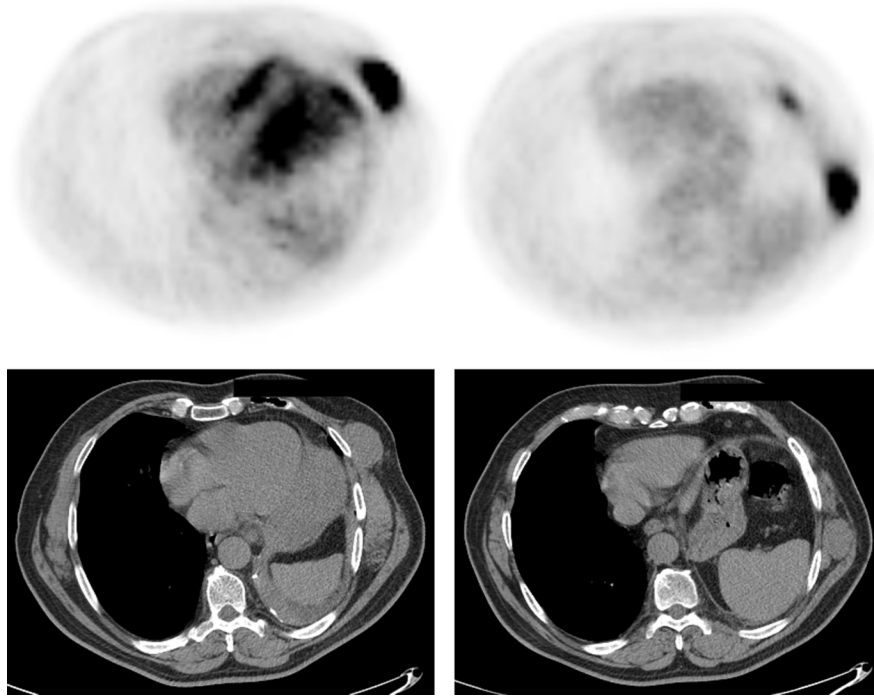


Figure 2

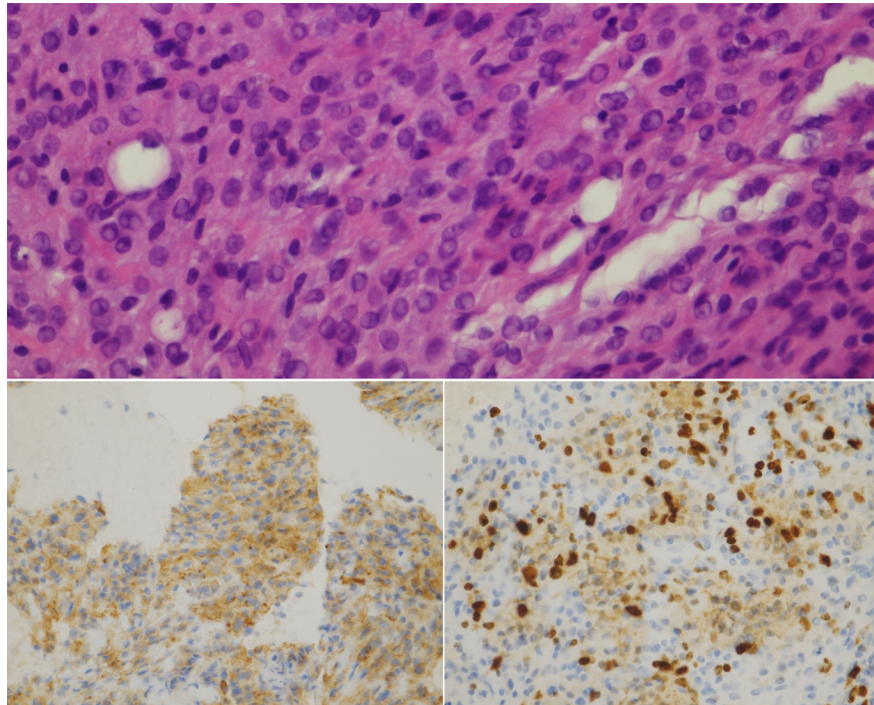


Figure 3

