

Lowering the Threshold for Left Bundle Branch Area Pacing

Lukasz Cerbin¹ and Lohit Garg²

¹University of Colorado Denver School of Medicine

²University of Colorado - Anschutz Medical Campus

April 28, 2022

Lowering the Threshold for Left Bundle Branch Area Pacing

Lukasz P. Cerbin, MD¹ and Lohit Garg, MD¹

¹ Division of Cardiac Electrophysiology, University of Colorado Anschutz Medical Campus, Aurora, Colorado, USA.

Relevant Disclosures: None

Funding: None

Corresponding Author: Lohit Garg, MD

Division of Cardiac Electrophysiology, University of Colorado Anschutz Medical Campus

12401, E. 17th Ave, Aurora, Colorado-80045

Email: Lohit.garg@cuanschutz.edu

Cardiac pacing remains the mainstay of therapy for conduction system disease and irreversible bradyarrhythmias. Due to known complications from chronic RV pacing and electromechanical dissociation^{1,2}, there has been a growing interest in physiologic pacing. While cardiac resynchronization therapy (CRT) with LV pacing from a lead in the coronary sinus has been shown to ameliorate some of the morbidity from RV septal pacing³, activation is still via myocyte to myocyte conduction rather than engaging the specialized conduction system. Furthermore, LV lead placement can be challenging and response to CRT is heterogeneous and difficult to predict⁴. And finally, CRT's role in patients with preserved LV systolic function has not been established.

In this light, there has recently been a substantial growth in conduction system pacing directly engaging the native His-Purkinje conduction system. This began with a case series published in 2000 demonstrating selective his bundle capture and subsequent permanent His bundle pacing (HBP) lead placement in patients with heart failure and tachycardia induced cardiomyopathy secondary to atrial fibrillation⁵. Additional studies demonstrated the feasibility and clinical benefit of HBP as a strategy for CRT^{6,7}. However, continued research revealed high capture thresholds and low R wave amplitudes, calling this technique into question⁸. Furthermore, HBP failed to demonstrate improved outcomes in patients with underlying LBBB, likely due to the presence of conduction disease distal to the site of capture⁹. Due to these concerns, the enthusiasm for HBP gradually waned, with a subsequent rise in interest in left bundle branch area pacing (LBBAP). This approach utilizes the same lead and implant technique to fix a lumenless pacing lead approximately 1.5 cm distal to the anatomical His bundle within the interventricular septum, directly engaging the left bundle.

In this issue, Mehta et al. describe a single center's experience of implantation of left bundle branch area pacing leads, complete with one year follow-up data. Their retrospective study included 65 patients over an 18 month period who received a 3830 Medtronic lead for LBBAP. Only patients with one year of follow

up data were included. Importantly, they excluded 7 patients in whom LBBAP implant was unsuccessful, resulting in a reported implant success rate of 91.8%. The reported procedure time was 72.7 +/- 28.8 minutes. The mean QRS duration decreased significantly in patients with pre-existing LBBB, was unchanged in those with pre-existing RBBB, and increased significantly in patients without pre-existing bundle branch block. At one year follow-up, they found a significantly higher capture threshold compared to threshold at implant ($p < 0.0001$), although they noted that the absolute increase (0.2-0.3 V) was relatively modest. No short or long-term complications related to device implant were identified.

This study underscores several important points regarding LBBAP. Firstly, procedural success is high, with the authors reporting an implant success rate of 91.8% in this study. Reasons for implant failure included unacceptably high pacing thresholds, inability to meet parameters used to ensure capture of the left bundle, and anatomic constraints in one patient that prohibited lead placement. This success rate is similar to that reported in other studies¹⁰. Other studies have found higher implant success rate with LBBAP as compared to HBP¹¹. Secondly, this success rate is likely easily reproducible as the implant technique does not require additional or specialized training, only a long delivery sheath and some familiarity with the mechanism to fix the 3830 lead to the interventricular septum. With preliminary data suggesting improved outcomes compared to traditional RV septal pacing¹² and the relative ease of procedural proficiency, it would seem that this technique could rapidly become the gold standard for pacemaker implantation.

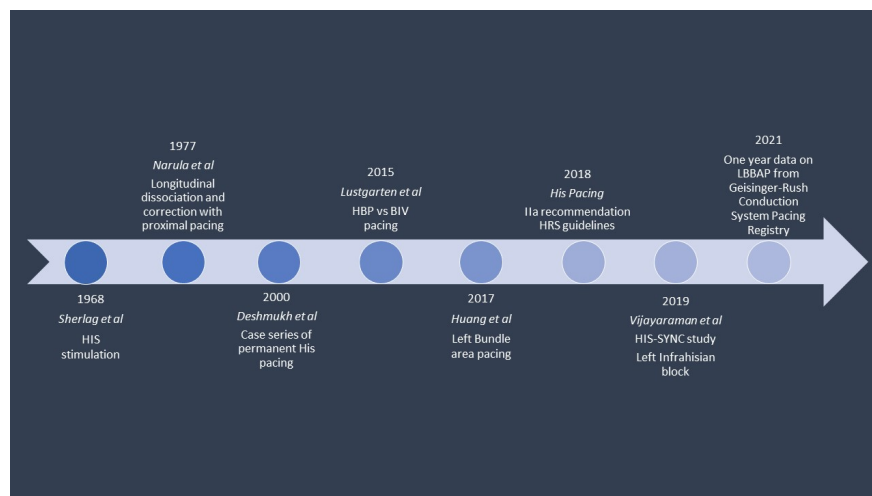
While there is great enthusiasm for LBBAP, several key questions remain. Firstly, this study, along with a recent publication from the Geisinger-Rush Conduction System Pacing Registry¹², are the first to publish one year data following LBBAP lead implant. While lead parameters were reported to be stable at one year in this study, longer term data are needed. Furthermore, in addition to data on long term lead parameters and clinical efficacy, long term safety outcomes will be important. Particularly, subclinical perforation of the helix into the LV may carry thrombotic risk and long term data on whether this increases stroke risk will be important¹³. One prior study found two cases of subclinical septal perforation occurring after LBBAP lead placement¹⁴. Another case report described a patient presenting with presyncope two weeks after device implant with perforation of the lead into the LV and associated lack of capture up to 3.5 V @ 0.4 ms (bipolar)¹⁵. The incidence and risk factors for these events has yet to be established and the associated morbidity, including stroke risk from thromboembolism, remains uncharacterized. Another question that needs to be addressed is that of extractability of LBBAP leads. While there have been few published reports of successful extraction of these leads¹⁶, these lumen-less leads represent unique challenges in terms of extraction tools and technique. More data is needed to characterize the approach and outcomes for extraction of LBBAP leads.

Finally, the criteria for left bundle capture, as opposed to left septal pacing, has yet to be firmly established, with both being included in the catch-all term “left bundle branch area pacing.” A recent study by Wu et al. utilized temporary HBP leads and LV septal mapping with multielectrode catheters during LBBAP lead implant to identify markers of selective LBBP¹⁷. They identified several useful parameters, including paced RBBB pattern (100% sensitive), LBB potential on the lead electrogram, abrupt shortening of stim-LV activation time (LVAT) and certain stim-LVAT times (which varied based on the presence or absence of an underlying LBBB). Another study from the same group utilized a decapolar coronary sinus catheter to examine differences in LV activation time and depolarization with left bundle capture versus left septal pacing, finding that the a model combining the presence of a LBBB potential on the lead coupled with a validated stim-LVAT had excellent test characteristics (AUC = 0.985) to differentiate conduction system from septal pacing¹⁸. In the current study, the authors reported 67.7% of patients with selective left bundle capture and 32.3% with left septal pacing when applying this algorithm. A scientific consensus on how to identify left bundle capture is essential to both study the long term clinical benefits in patients undergoing LBBAP implantation as well as establishing criteria to guide implanting physicians attempting to achieve selective left bundle capture.

In summary, left bundle branch area pacing remains an exciting and burgeoning area within cardiac electrophysiology. This study by Mehta et al. demonstrated stable and acceptable lead parameters one year

after LBBAP implantation, adding evidence of the long term safety and efficacy of this technique. Several questions remain, including longer term efficacy, the incidence of subacute and chronic complications, the ability to extract these leads when indicated, and the effect of LBBAP clinical outcomes. Furthermore, rigorous definitions for left bundle capture and left septal pacing need to be agreed upon. However, if these data can be replicated on a larger scale and longer term data shows similar safety and efficacy, LBBAP may likely represent the gold standard for pacing for bradyarrhythmia indications in the near future.

Figure 1: Evolution of Conduction System Pacing



Conflict of interest: None

References:

1. Wilkoff BL, Cook JR, Epstein AE, et al. Dual-chamber pacing or ventricular backup pacing in patients with an implantable defibrillator: the Dual Chamber and VVI Implantable Defibrillator (DAVID) Trial. *Jama* 2002;288(24):3115-23. (In eng). DOI: 10.1001/jama.288.24.3115.
2. Sweeney MO, Hellkamp AS, Ellenbogen KA, et al. Adverse effect of ventricular pacing on heart failure and atrial fibrillation among patients with normal baseline QRS duration in a clinical trial of pacemaker therapy for sinus node dysfunction. *Circulation* 2003;107(23):2932-7. (In eng). DOI: 10.1161/01.Cir.0000072769.17295.B1.
3. Prinzen FW, Vernooy K, Auricchio A. Cardiac resynchronization therapy: state-of-the-art of current applications, guidelines, ongoing trials, and areas of controversy. *Circulation* 2013;128(22):2407-18. (In eng). DOI: 10.1161/circulationaha.112.000112.
4. Daubert C, Behar N, Martins RP, Mabo P, Leclercq C. Avoiding non-responders to cardiac resynchronization therapy: a practical guide. *Eur Heart J* 2017;38(19):1463-1472. (In eng). DOI: 10.1093/eur-heartj/ehw270.
5. Deshmukh P, Casavant DA, Romanynshyn M, Anderson K. Permanent, direct His-bundle pacing: a novel approach to cardiac pacing in patients with normal His-Purkinje activation. *Circulation* 2000;101(8):869-77. (In eng). DOI: 10.1161/01.cir.101.8.869.
6. Lustgarten DL, Crespo EM, Arkhipova-Jenkins I, et al. His-bundle pacing versus biventricular pacing in cardiac resynchronization therapy patients: A crossover design comparison. *Heart Rhythm* 2015;12(7):1548-57. (In eng). DOI: 10.1016/j.hrthm.2015.03.048.

7. Sharma PS, Dandamudi G, Herweg B, et al. Permanent His-bundle pacing as an alternative to biventricular pacing for cardiac resynchronization therapy: A multicenter experience. *Heart Rhythm* 2018;15(3):413-420. (In eng). DOI: 10.1016/j.hrthm.2017.10.014.
8. Teigeler T, Kolominsky J, Vo C, et al. Intermediate-term performance and safety of His-bundle pacing leads: A single-center experience. *Heart Rhythm* 2021;18(5):743-749. (In eng). DOI: 10.1016/j.hrthm.2020.12.031.
9. Upadhyay GA, Vijayaraman P, Nayak HM, et al. His Corrective Pacing or Biventricular Pacing for Cardiac Resynchronization in Heart Failure. *J Am Coll Cardiol* 2019;74(1):157-159. (In eng). DOI: 10.1016/j.jacc.2019.04.026.
10. Vijayaraman P, Subzposh FA, Naperkowski A, et al. Prospective evaluation of feasibility and electrophysiologic and echocardiographic characteristics of left bundle branch area pacing. *Heart Rhythm* 2019;16(12):1774-1782. DOI: <https://doi.org/10.1016/j.hrthm.2019.05.011>.
11. Zhuo W, Zhong X, Liu H, et al. Pacing Characteristics of His Bundle Pacing vs. Left Bundle Branch Pacing: A Systematic Review and Meta-Analysis. *Front Cardiovasc Med* 2022;9:849143. (In eng). DOI: 10.3389/fcvm.2022.849143.
12. Sharma PS, Patel NR, Ravi V, et al. Clinical outcomes of left bundle branch area pacing compared to right ventricular pacing: Results from the Geisinger-Rush Conduction System Pacing Registry. *Heart Rhythm* 2022;19(1):3-11. (In eng). DOI: 10.1016/j.hrthm.2021.08.033.
13. Ponnusamy SS, Basil W, Vijayaraman P. Electrophysiological characteristics of septal perforation during left bundle branch pacing. *Heart Rhythm* 2022 (In eng). DOI: 10.1016/j.hrthm.2022.01.018.
14. Chen X, Wei L, Bai J, et al. Procedure-Related Complications of Left Bundle Branch Pacing: A Single-Center Experience. *Front Cardiovasc Med* 2021;8:645947. (In eng). DOI: 10.3389/fcvm.2021.645947.
15. Ravi V, Larsen T, Ooms S, Trohman R, Sharma PS. Late-onset interventricular septal perforation from left bundle branch pacing. *HeartRhythm Case Rep* 2020;6(9):627-631. (In eng). DOI: 10.1016/j.hrcr.2020.06.008.
16. Garnreiter J, Whitaker P, Pilcher T, Etheridge S, Saarel E. Lumenless pacing leads: performance and extraction in pediatrics and congenital heart disease. *Pacing Clin Electrophysiol* 2015;38(1):42-7. (In eng). DOI: 10.1111/pace.12508.
17. Wu S, Chen X, Wang S, et al. Evaluation of the Criteria to Distinguish Left Bundle Branch Pacing From Left Ventricular Septal Pacing. *JACC Clin Electrophysiol* 2021;7(9):1166-1177. (In eng). DOI: 10.1016/j.jacep.2021.02.018.
18. Chen X, Qian Z, Zou F, et al. Differentiating left bundle branch pacing and left ventricular septal pacing: An algorithm based on intracardiac electrophysiology. *J Cardiovasc Electrophysiol* 2022;33(3):448-457. (In eng). DOI: 10.1111/jce.15350.