

A 44-year-Old Male with Esophageal Ulcer

Delvise Fogwe¹, Shah Aditya¹, and Matthew Ho¹

¹Mayo Clinic Rochester

April 18, 2022

A 44-year-Old Male with Esophageal Ulcer

Question: A 44-year-old male was admitted for acute gastrointestinal bleed, intermittent esophageal dysphagia, and odynophagia. His past medical history was significant for dermatomyositis, for which he was on mycophenolate but had previously received prednisone and methotrexate. The treatment for his dermatomyositis had been complicated by pancytopenia with Hemoglobin 6.8 (13.2 - 16.6 g/dL), platelet 73 (135 - 317 x10⁹/L), and white blood cells 1.9(3.4 - 9.6 x10⁹/L). He underwent esophagogastroduodenoscopy (EGD), which showed a deep esophageal ulcer on the background of diffuse white plaques in the middle third of the esophagus and a non-bleeding large cratered clean-based gastric antral ulcer (Figure 1, A&B). Barium swallow showed a sac-like structure consistent with the ulcer without contrast leakage to suggest a fistula (Figure 1, C). What is the most likely diagnosis?

Answer: This is a classic presentation of Cytomegalovirus (CMV) esophageal ulcer. The biopsy of the ulcer revealed positive CMV immunostaining, with negative immunostaining for Herpes simplex virus and fungus. His quantitative CMV DNA was 20400 IU/mL (Reference range Undetected), and his HIV test was negative. CMV predominantly causes opportunistic infection in immunosuppressed patients. It mainly causes gastrointestinal symptoms, with about 12.9% of patients presenting with esophageal disease. Unlike other infectious esophageal ulcers, CMV tends to cause one or more giant (>1cm) ulcers that may be flat, ovoid, or diamond-shaped.

References

- Yeh PJ, Wu RC, Chiu CT, et al. Cytomegalovirus Diseases of the Gastrointestinal Tract. *Viruses*. 2022;14(2):352. Published 2022 Feb 8. doi:10.3390/v14020352
- You DM, Johnson MD. Cytomegalovirus infection and the gastrointestinal tract. *Curr Gastroenterol Rep*. 2012 Aug;14(4):334-42. doi: 10.1007/s11894-012-0266-4. PMID: 22588614.

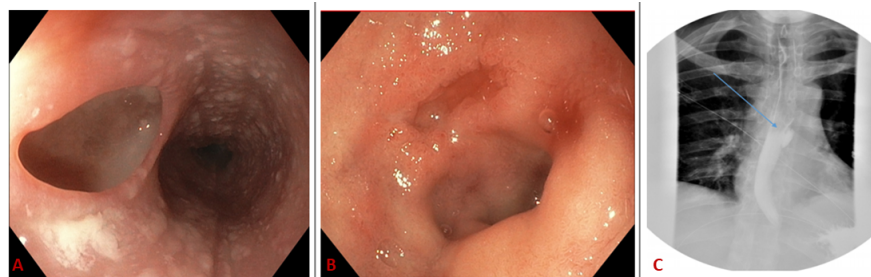


Figure 1: (A) Deep esophageal ulcer (B) Gastric antral ulcer (C) Barium swallow study.