

Growing Teratoma Syndrome: Two case reports

anju shrestha¹, Hari Dhakal², Sirish Pandey³, Kapendra Amatya³, Sudip Shrestha³, Prakash Tiwari³, and Srijana Lama³

¹Nepal cancer Hospital and Research center

²Nepal Cancer Hospital and Research center.

³Nepal Cancer Hospital and Research Center

December 8, 2021

Abstract

We present two cases of nine and twenty-seven years old girls with recurrence of immature teratoma after an incomplete surgical staging. In both cases, there were huge abdominopelvic masses despite decrease in tumor markers with chemotherapy. Complete surgical resection of these masses was done, and histopathology showed only mature teratoma.

Hosted file

manuscript case report.docx available at <https://authorea.com/users/440929/articles/548587-growing-teratoma-syndrome-two-case-reports>

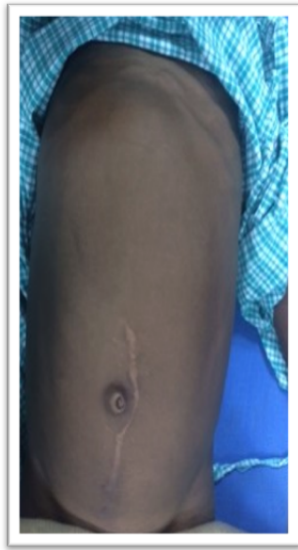


Figure 1 A

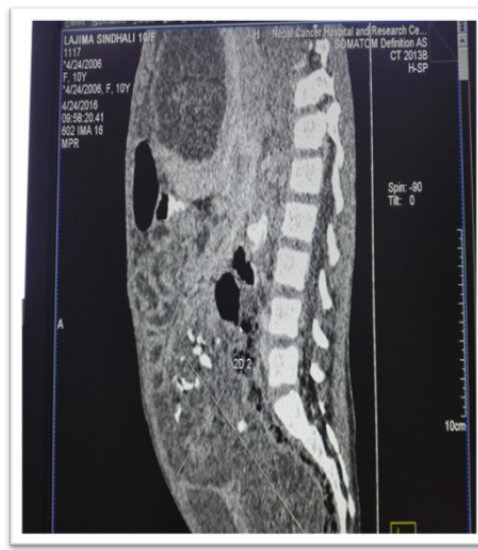

Figure 1 B

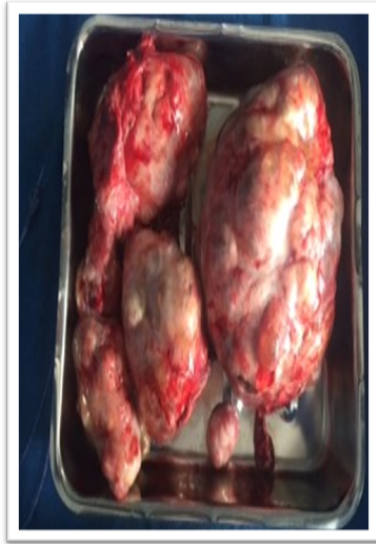

Figure 2 A

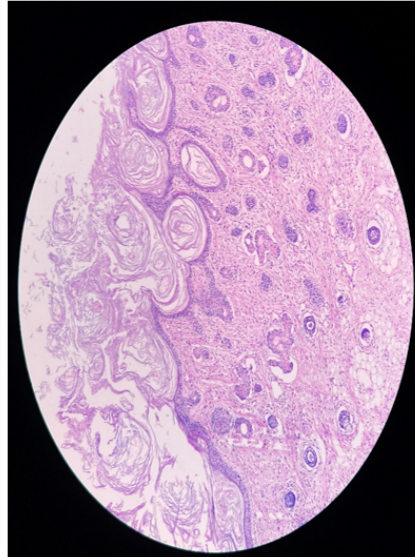


Figure 2 B

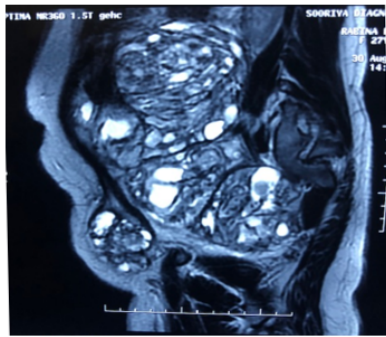


Figure 3 A

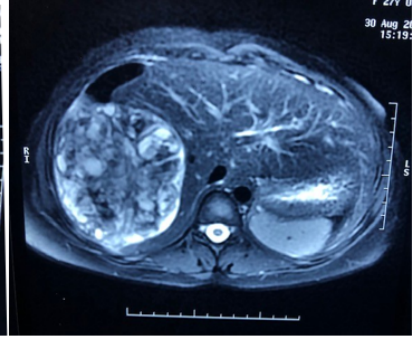


Figure 3 B

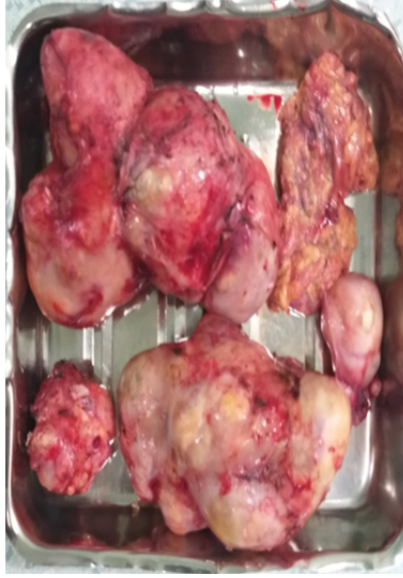

Figure 4 A

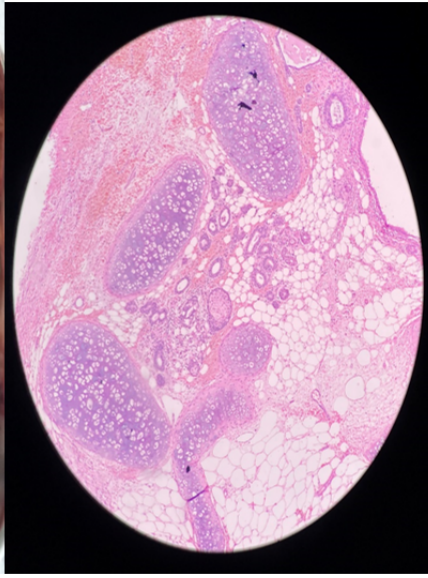


Figure 4 B