

Mucormycosis infection in severe COVID-19 patient with multiple underlying health conditions

Zahra Heydarifard¹, Moslem Safaei², Sevrin Zadheidar¹, and Nazanin Zahra Shafiei-Jandaghi¹

¹Tehran University of Medical Sciences

²Shahid Sadoughi University of Medical Sciences and Health Services

July 15, 2021

Abstract

Coronavirus disease 2019 (COVID-19) is a fearsome infectious disease which cause some excessive complications along with it. the authors present a case of acute invasive rhino-orbital mucormycosis in a 62-year-old man with severe COVID-19 pneumonia, who had a history of uncontrolled diabetes mellitus along with ketoacidosis and nephropathy.

Introduction:

Coronavirus disease 2019 (COVID-19) has infected >180 million people globally and over 3 million in Iran (1). SARS-CoV-2 causing COVID-19, can lead to severe infections among patients who have underlying health conditions (2).

It is suggested that SARS-CoV-2 might enhance susceptibility to pulmonary fungal coinfections (3).

Mucormycosis is an angioinvasive disease caused by a fungi of the order Mucorales like *Rhizopus*, *Mucor*, *Rhizomucor*, *Cunninghamella* and *Absidia* (4).

In Iran prevalence of mucormycosis for the last six years has been 29.7 cases/year (5). Mucormycosis is a rare infection with high mortality rate (20-100%). Immunocompromised patients such as the ones with hematological malignancies, recipients of hematopoietic stem cell (HSCT), patients with diabetes mellitus and ketoacidosis are susceptible to highly fatal mucormycosis infection (6, 7).

While super-infections and co-infections in COVID-19 pneumonia are still under investigation, sporadic reports of mucormycosis in COVID-19 patients have been published.

Herein, we present a case of severe COVID-19 with multiple underlying health conditions who was co-infected with rhino-orbital mucormycosis.

Case presentation:

A 62-year-old man with a past medical history of type 2 diabetes mellitus, hypertension and diabetic nephropathy under hemodialysis, referred to the emergency department of Valiasr hospital, Tehran, Iran on April, 29, 2021. He presented with shortness of breath and hypoxia. He had two histories of surgery, coronary artery bypass grafting (CABG) and cataract surgery for both eyes. On admission, his vital signs showed a temperature of 37.3°C, heart rate of 100, respiratory rate of 24, blood pressure of 117/63 mm Hg and pulse oximetry of 60%. Moreover, crackle sounds were heard when he was breathing. Upon examination, he was diagnosed with acute respiratory distress syndrome (ARDS), so he was admitted to intensive care

unit (ICU) and stayed there for 10 days. On day 8 of hospitalization, the patient complained of a headache and pain in the right eye followed by a more severe headache and edema in the right eye the next day.

On day 10 of hospitalization, his health condition exacerbated. He had vision loss on the right eye and proptosis in both eyes. In eye examination chemosis, conjunctivitis and cherry red spot in the right eye were seen, which represented central retinal artery occlusion (CRAO).

He was transferred to ophthalmology center (Rasoul Akram hospital) for endoscopic surgical debridement. Unfortunately, he expired on hospital day 30.

Investigations:

The results of blood chemistry, complete blood count (CBC) and blood gas tests were shown in Table 1. The patient was found to have a high white blood cell count of 11300 mm^3 with 91% neutrophils and 7% lymphocytes. Serum chemistry was significant for blood sugar 291mg/dL, bicarbonate 17.8 mEq/L, creatinine 5.4 mg/dL, BUN 46.7mg/dL and lactate dehydrogenase 580 U/L. Laboratory investigations revealed nephropathy and hyperglycemia with diabetic ketoacidosis (DKA).

The COVID-19 reverse transcription-polymerase chain reaction (RT-PCR) test was positive for viral RNA. A chest computed tomography (CT) was performed and revealed bilateral peripheral ground-glass opacification with extensive lung parenchymal involvement (Figure 1). Besides, he was diagnosed with COVID-19 pneumonia. He was classified in severe COVID-19 infection group. After one week, RT-PCR was still positive.

Neurology consulting was performed and brain CT, sinus CT, brain MRI (magnetic resonance imaging), and brain MRA (Magnetic resonance angiography) were ordered. The face CT revealed extensive opacification of right ethmoid, maxillary sinus and nasal septum. There was also obstruction in right ostiomeatal complex (OMC). This can be seen in Figure 2. An MRI and MRA showed that brain tissue was normal (not shown).

To diagnose meningitis, lumbar puncture (LP) was done and cerebrospinal fluid (CSF) was collected to be cultured. The CSF culture was negative for any bacterial infection. However, cytology examination showed acute inflammation in CSF sample.

The clinical and radiographic findings were highly suspicious for acute invasive fungal rhinosinusitis with orbital involvement. Thus, sinuses were debrided and the specimen was sent for culturing and histopathology examination. On histopathology examination, broad aseptate filamentous fungal hyphae was seen and therefore Mucormycosis infection was confirmed.

Treatment:

For COVID-19 infection, the treatment initiated with Remdesivir IV with a loading dose of 200 mg, followed by 100 mg/day after each hemodialysis for 10 days, Dexamethasone 16 mg \ twice a day, Ivermectin 12 mg STAT, N-Acetyl Cysteine (NAC) was given by IV infusion, 2g twice a day and also colchicine 0.5 mg twice a day. Oxygen therapy was done by oxygen mask with reservoir bags (OMR) and oxygen saturation level improved to 88% on day 6 of hospitalization.

For diabetes, Insulin glargine 30 units in morning, 16 units at night and Insulin aspart before each meal was prescribed (18, 18, 16 unit).

For hypertension treatment, Amlodipine 5 mg daily and Prazosin 0.25 mg three times a day were ordered.

Liposomal Amphotericin B was started for him (5mg/Kg/day) as a treatment for mucormycosis infection.

Discussion:

Up to now, there are limited data about the impact of COVID-19 on mucormycosis or other fungal infections. On the one hand, the robust inflammatory immune response following COVID-19 and usage of immunosuppressive drugs afterwards, provides a favorable condition for development of fungal co-infections. On the other hand, it is suggested that venous thromboembolism (VTE) caused by COVID-19 infection leads to mechanical ventilation, central venous catheterization, and surgeries, all of which could damage elastic

lamina of blood vessels and eventually trigger the propagation of mucorales (3). Furthermore, comorbidities such as diabetes mellitus and diabetic nephropathy are risk factors for both COVID-19 and mucormycosis (8).

This case report is consistent with other case reports in which diabetes mellitus was a predisposing condition regarding SARS-CoV-2 and mucormycosis co-infection. Besides, this case had multiple underlying health conditions including diabetic ketoacidosis, diabetic nephropathy, hypertension and history of CABG surgery. All of these conditions, increase COVID-19 severity and the risk of co-infection or superinfection with other microorganisms (9). Unfortunately, this case had a poor prognosis due to extensive involvement of rhino-orbital mucormycosis and ARDS and passed away after one month of hospitalization.

Based on a broad literature search, the presented case had some unique features compared to the similar reported cases. First of all, Diabetic nephropathy followed by hemodialysis has not been reported in concurrent infection of COVID-19 and mucormycosis. Secondly, limited cases of diabetic ketoacidosis as a comorbidity in SARS-CoV-2 co-infected with mucormycosis have been reported previously (10, 11). The presented case was the only case with uncontrolled diabetes mellitus, diabetic ketoacidosis, diabetic nephropathy under hemodialysis and hypertension who was suffering from rhino-orbital mucormycosis following severe COVID-19 infection. It should be noted that in reports from different countries other underlying health conditions have also been associated with mucormycosis following COVID-19 such as; Hematological malignancies, Hypothyroidism, Asthma and obesity with median age of 53.4 and male sex comprising the majority of the cases (12-19).

Up to July 4, four cases of rhino-orbital–cerebral mucormycosis following COVID-19 have been reported in Iran. The median age of the patients was 51.2 years. Besides, 3 out of 4 were women. Diabetes mellitus was the most historical condition (3 of 4). Of these four cases, one death was reported. Amphotericin B was prescribed for all of them as the first line treatment for mucormycosis infection(20-22).

Mucormycosis is a serious opportunistic fungal infection that could lead to rhino-orbital, gastrointestinal, pulmonary, renal, cutaneous and disseminated infections. The infection enters the host via respiratory tract. Since it has a noticeable affinity for arteries it grows in internal elastic lamina, which triggers thrombosis and infarction (23). The disease can progress from nose and sinuses directly or through vascular occlusion. Invasion through superior orbital fissure, ophthalmic vessels, cribriform plate, carotid artery or possibly via a perineural route can involve intracranial part (24).

Necrotic tissue surgical debridement, treatment with liposomal amphotericin B as an antifungal therapy and risk factors control were suggested to improve survival (25).

Since COVID-19 pandemic is continuing in Iran and mass vaccination has not been started yet, co-infection of SARS-CoV-2 and other microorganisms should be taken under consideration. Prescribing immunosuppressants for COVID-19 patients with underlying health conditions should be done more cautiously along with continuous monitoring. In spite of massive researches on COVID-19 management performing all around the world, extensive researches are needed regarding better prevention and management of opportunistic infections among COVID-19 patients, yet.

Conclusion:

We described a case with multiple underlying health conditions, who contracted SARS-CoV-2 and mucormycosis coinfection. Unfortunately, despite of surgical debridement and antifungal and antiviral therapies, he could not survive. We suggested that uncontrolled diabetes milieu made the patient susceptible to both severe COVID-19 and mucormycosis. Prevention and management guideline as well as prophylactic treatment protocols are needed for similar complicated patients.

Acknowledgement:

The authors would like to thank Dr. Kaveh and Dr. Rouhani in Infectious Disease Section of Valiasr hospital, Tehran, Iran, for their contribution to this research and the patient and his family for their patience and

co-operation.

Conflict of interest:

The authors declare that there are no conflicts of interests

Author contribution:

ZH: concept, investigating, manuscript preparation. MS: Involvement in the clinical case, data collection. SZ: supportive role in manuscript preparation and revision. NZSH: reviewed the paper critically and comments were included. All authors approved the final version of the manuscript before submission.

Ethical approval and consent to participate:

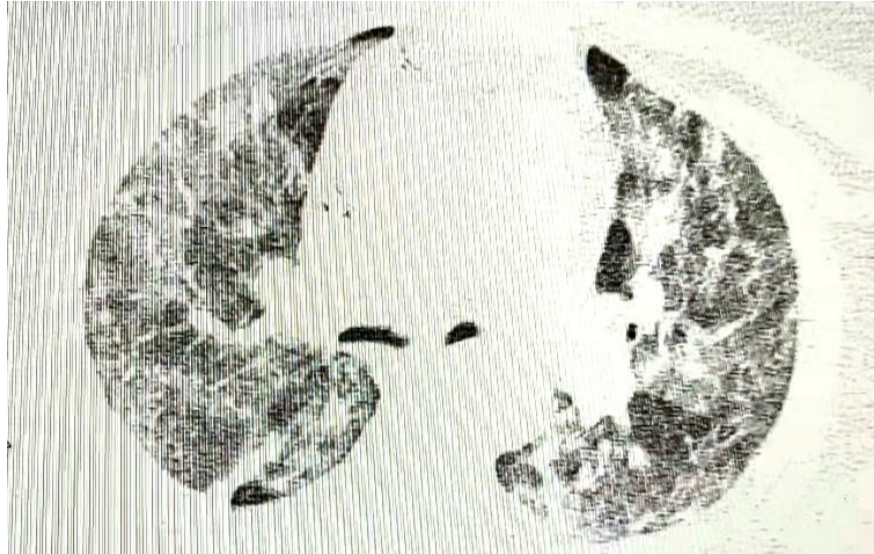
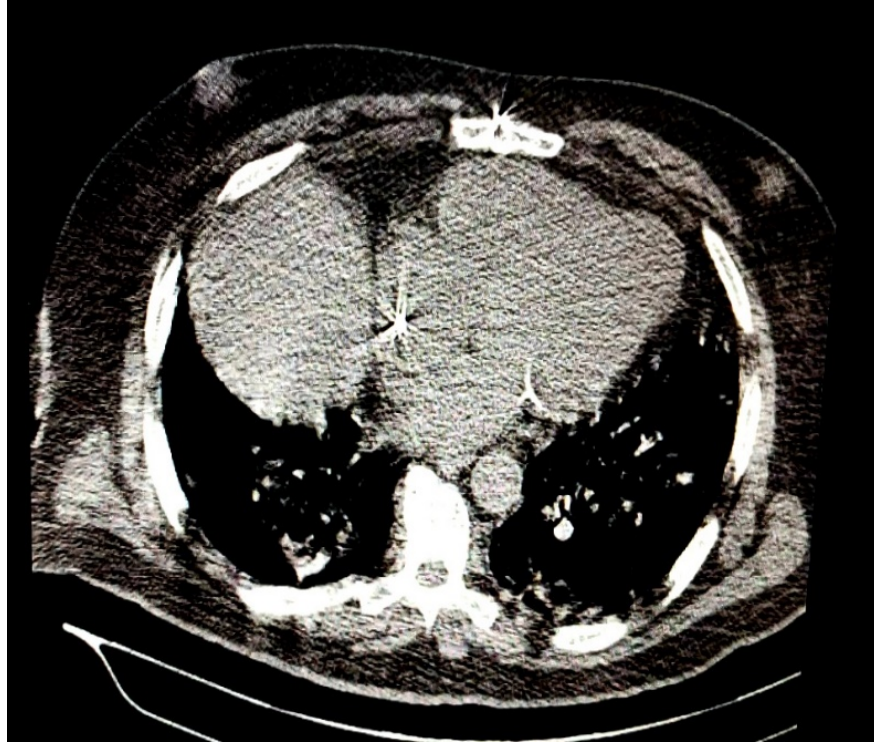
The study was conducted in accordance with the Declaration of Helsinki and national and institutional standards and it was approved by Valiasr hospital medical ethics committee. patient signed written informed consents and accepted the publication of clinical data for research.

Table 1. Ancillary tests during patient hospitalization.

Blood plasma/serum	result	Reference serum (normal)
Sodium	140 mEq/L	135 - 145 mEq/L
Potassium	4.1 mEq/L	3.5 - 5.0 mEq/L
BS	291mg/dL (high)	70-140 mg/dL
FBS	186 mg/dL(high)	70-110 mg/dL
Creatinine	5.4 mg/dL (high)	0.5 - 1.5 mg/dL
BUN	46.7mg/dL(high)	7 - 20 mg/dL
Magnesium	3.8 mEq/L(high)	1.8 - 2.6 mEq/L
CRP	89.1mg/l (high)	Less than 6 mg/L
SGOT	189 U/L (high)	Less than 40 U/L
SGPT	61 U/L (high)	Less than 40 U/L
Alkaline phosphatase	219 U/L	80-306 U/L
phosphorus	5.3 mg/dl (high)	3.4 to 4.5 mg/dl
Calcium	8.6 mg/dL	8.5 - 10.5 mg/dL
Bicarbonate	17.8 mEq/L (low)	22 - 26 mEq/L
PCO2	41.7 mmHg	35-40 mmHg
PH	7.23	7.31-7.41
LDH	580 U/L (high)	140-280 U/L
D-Dimer	positive	Negative
WBC	11300 mm ³ (high)	4000-10000/mm ³
R B C	4.65 mill//mm ³	4.5-6.5 /mm ³
Hb	11.5 (low)	13.5-18 g/dl
Hct	36.0 %	42-52 %
ESR	39 mm/hr	Less than 10
Platelet	170000/ mm ³	150000-450000 mm ³

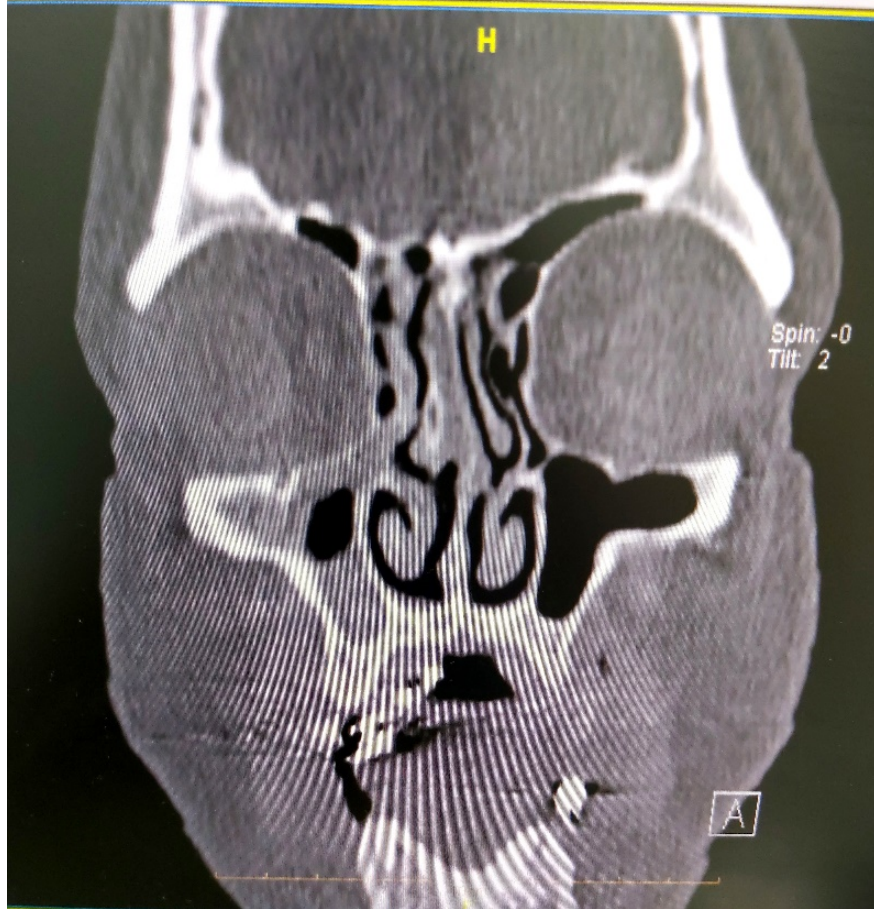
BS: blood sugar; FBS: fast blood sugar; BUN: blood urea nitrogen; CRP: c-reactive protein; SGOT: serum glutamic-oxaloacetic transaminase; SGPT: serum glutamic-pyruvic transaminase; LDH: lactate dehydrogenase; Hb: hemoglobin; Hct: hematocrit; ESR: Erythrocyte sedimentation rate

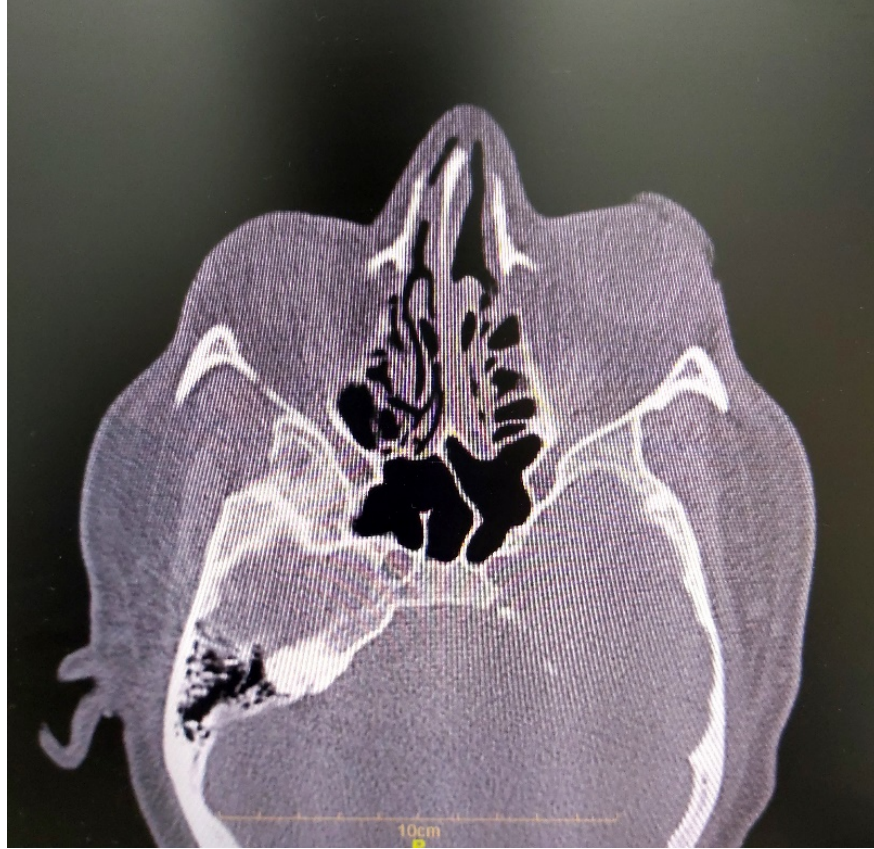
Fig1. Computed tomography showing bilateral peripheral ground-glass opacification (GGO) and thickness in the interalveolar septum with extensive lung parenchymal involvement in the corresponding lung window (A) and mediastinal



sections (B).

Fig 2. Contrast enhanced CT showing mucoperiosteal thickening in the right maxillary, ethmoid sinus and blocked right ostiomeatal complex (OMC). Coronal section (A) Axial sections (B)





References:

1. Dong E, Du H, Gardner L. An interactive web-based dashboard to track COVID-19 in real time. *The Lancet infectious diseases*. 2020;20(5):533-4.
2. Elezkurtaj S, Greuel S, Ihlow J, Michaelis EG, Bischoff P, Kunze CA, et al. Causes of death and comorbidities in hospitalized patients with COVID-19. *Scientific Reports*. 2021;11(1):1-9.
3. Pandiar D, Kumar NS, Anand R, Kamboj M, Narwal A, Shameena P. Does COVID 19 generate a milieu for propagation of mucormycosis? *Medical Hypotheses*. 2021:110613.
4. Eucker J, Sezer O, Graf B, Possinger K. Mucormycoses. *Mycoses*. 2001;44(7-8):253-60.
5. Dolatabadi S, Ahmadi B, Rezaei-Matehkolaei A, Zarrinfar H, Skiada A, Mirhendi H, et al. Mucormycosis in Iran: A six-year retrospective experience. *Journal de mycologie medicale*. 2018;28(2):269-73.
6. Ribes JA, Vanover-Sams CL, Baker DJ. Zygomycetes in human disease. *Clinical microbiology reviews*. 2000;13(2):236-301.
7. Ibrahim AS, Spellberg B, Walsh TJ, Kontoyiannis DP. Pathogenesis of mucormycosis. *Clinical Infectious Diseases*. 2012;54(suppl_1):S16-S22.
8. John TM, Jacob CN, Kontoyiannis DP. When uncontrolled diabetes mellitus and severe COVID-19 converge: the perfect storm for mucormycosis. *Journal of Fungi*. 2021;7(4):298.
9. Singh AK, Singh R, Joshi SR, Misra A. Mucormycosis in COVID-19: a systematic review of cases reported worldwide and in India. *Diabetes & Metabolic Syndrome: Clinical Research & Reviews*. 2021.

10. Alekseyev K, Didenko L, Chaudhry B. Rhinocerebral mucormycosis and COVID-19 pneumonia. *Journal of medical cases*. 2021;12(3):85.
11. Waizel-Haiat S, Guerrero-Paz JA, Sanchez-Hurtado L, Calleja-Alarcon S, Romero-Gutierrez L. A case of fatal rhino-orbital mucormycosis associated with new onset diabetic ketoacidosis and COVID-19. *Cureus*. 2021;13(2).
12. Hanley B, Naresh KN, Roufousse C, Nicholson AG, Weir J, Cooke GS, et al. Histopathological findings and viral tropism in UK patients with severe fatal COVID-19: a post-mortem study. *The Lancet Microbe*. 2020;1(6):e245-e53.
13. Mehta S, Pandey A. Rhino-orbital mucormycosis associated with COVID-19. *Cureus*. 2020;12(9).
14. do Monte Junior ES, Dos Santos MEL, Ribeiro IB, de Oliveira Luz G, Baba ER, Hirsch BS, et al. Rare and fatal gastrointestinal mucormycosis (Zygomycosis) in a COVID-19 patient: a case report. *Clinical endoscopy*. 2020;53(6):746.
15. Placik DA, Taylor WL, Wnuk NM. Bronchopleural fistula development in the setting of novel therapies for acute respiratory distress syndrome in SARS-CoV-2 pneumonia. *Radiology Case Reports*. 2020;15(11):2378-81.
16. Werthman-Ehrenreich A. Mucormycosis with orbital compartment syndrome in a patient with COVID-19. *The American journal of emergency medicine*. 2021;42:264. e5-. e8.
17. Mekonnen ZK, Ashraf DC, Jankowski T, Grob SR, Vagefi MR, Kersten RC, et al. Acute invasive rhino-orbital mucormycosis in a patient with COVID-19-associated acute respiratory distress syndrome. *Ophthalmic plastic and reconstructive surgery*. 2021;37(2):e40.
18. Pasero D, Sanna S, Liperi C, Piredda D, Branca GP, Casadio L, et al. A challenging complication following SARS-CoV-2 infection: a case of pulmonary mucormycosis. *Infection*. 2020:1-6.
19. Zurl C, Hoenigl M, Schulz E, Hatzl S, Gorkiewicz G, Krause R, et al. Autopsy proven pulmonary mucormycosis due to *Rhizopus microsporus* in a critically ill COVID-19 patient with underlying hematological malignancy. *Journal of Fungi*. 2021;7(2):88.
20. Veisi A, Bagheri A, Eshaghi M, Rikhtehgar MH, Rezaei Kanavi M, Farjad R. Rhino-orbital mucormycosis during steroid therapy in COVID-19 patients: a case report. *European Journal of Ophthalmology*. 2021:11206721211009450.
21. Karimi-Galougahi M, Arastou S, Haseli S, editors. *Fulminant mucormycosis complicating coronavirus disease 2019 (COVID-19)*. International forum of allergy & rhinology; 2021: Wiley Online Library.
22. Tabarsi P, Khalili N, Pourabdollah M, Sharifynia S, Naeini AS, Ghorbani J, et al. COVID-19 associated rhinosinusitis mucormycosis due to *Rhizopus oryzae*: A rare but potentially fatal infection occurring after treatment with corticosteroids. 2021.
23. Gupta S, Goyal R, Kaore NM. Rhino-orbital-cerebral mucormycosis: battle with the deadly enemy. *Indian Journal of Otolaryngology and Head & Neck Surgery*. 2020;72(1):104-11.
24. Bawankar P, Lahane S, Pathak P, Gonde P, Singh A. Central retinal artery occlusion as the presenting manifestation of invasive rhino-orbital-cerebral mucormycosis. *Taiwan journal of ophthalmology*. 2020;10(1):62.
25. Hirabayashi KE, Idowu OO, Kalin-Hajdu E, Oldenburg CE, Brodie FL, Kersten RC, et al. Invasive fungal sinusitis: risk factors for visual acuity outcomes and mortality. *Ophthalmic Plastic & Reconstructive Surgery*. 2019;35(6):535-42.

Hosted file

figure 1.docx available at <https://authorea.com/users/425763/articles/530496-mucormycosis-infection-in-severe-covid-19-patient-with-multiple-underlying-health-conditions>

Hosted file

figure2.docx available at <https://authorea.com/users/425763/articles/530496-mucormycosis-infection-in-severe-covid-19-patient-with-multiple-underlying-health-conditions>