

Prominent Mobile Crista Terminalis: A Right Atrial Pitfall

Eustaquio Maria Onorato¹, Luca Grancini¹, Paolo Olivares¹, and Antonio L. Bartorelli¹

¹Centro Cardiologico Monzino Istituto di Ricovero e Cura a Carattere Scientifico

October 19, 2020

Abstract

Intraprocedural rotational intracardiac echocardiography by Ultra ICE allowed qualitative information consistent with a prominent mobile Crista Terminalis. The correct diagnosis of this right atrial pitfall zeroed the risk to mistake it for tumors or thrombi, avoiding needlessly costly additional investigations.

Hosted file

Manuscript.pdf available at <https://authorea.com/users/338955/articles/487558-prominent-mobile-crista-terminalis-a-right-atrial-pitfall>

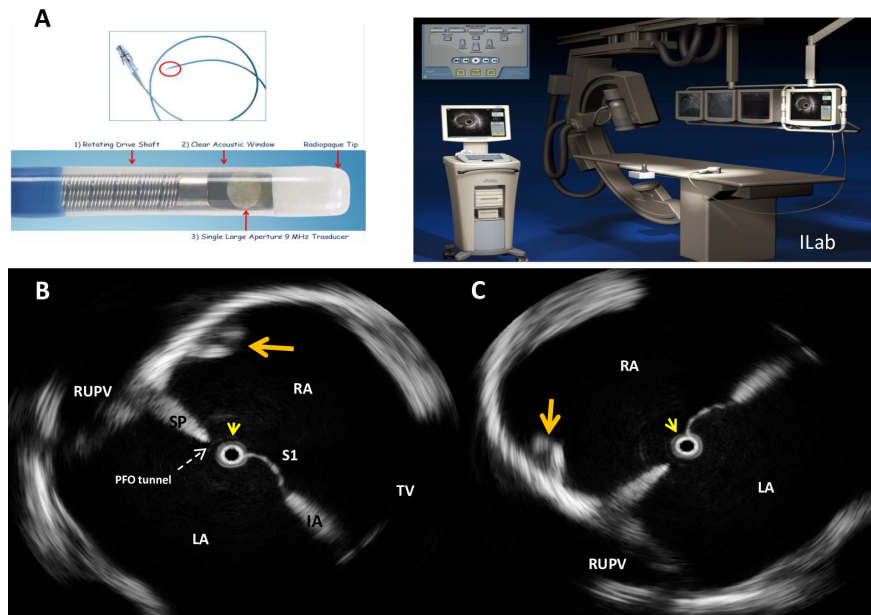


Figure 1.

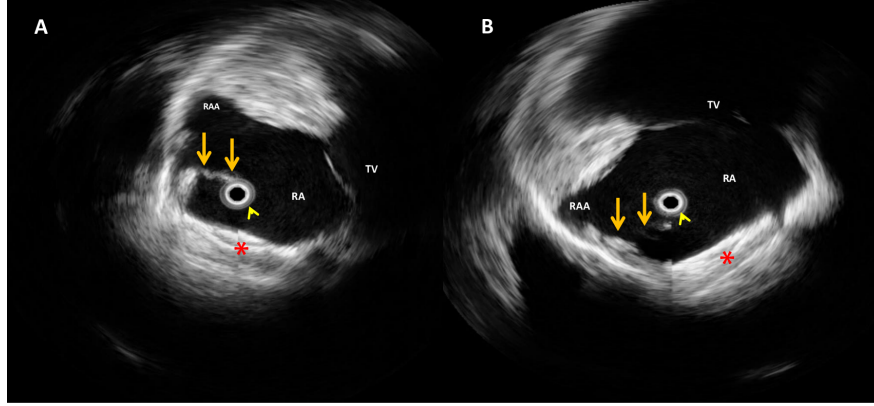


Figure 2.