

# A Parent's Nightmare

Kristin Foss<sup>1</sup>

<sup>1</sup>Louisiana State University

April 17, 2023



# A Parent's Nightmare

KRISTIN FOSS<sup>1</sup>

1. Louisiana State University

READ REVIEWS

WRITE A REVIEW

**CORRESPONDENCE:**

[kfoss2@lsu.edu](mailto:kfoss2@lsu.edu)

**DATE RECEIVED:**

September 20, 2015

**DOI:**

10.15200/winn.144280.05009

**ARCHIVED:**

September 20, 2015

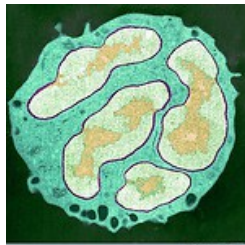
**KEYWORDS:**

Anti-NMDR encephalitis, case study

**CITATION:**

Kristin Foss, A Parent's Nightmare, *The Winnower* 2:e144280.05009, 2015, DOI: [10.15200/winn.144280.05009](https://doi.org/10.15200/winn.144280.05009)

© Foss This article is distributed under the terms of the [Creative Commons Attribution 4.0 International License](https://creativecommons.org/licenses/by/4.0/), which permits unrestricted use, distribution, and redistribution in any medium, provided that the original author and source are credited.



By Kristin Foss

It all started with a mysterious rash, which quickly escalated into every parent's nightmare.

Recently, a 20-month-old boy went from being a vivacious toddler to an incapacitated child, losing his spark in a matter of days. First, red bumps developed all over his face, body and arms. But when the mysterious illness progressed to uncontrolled tongue thrusting and hand twitching, his family immediately sought medical attention. As the mysterious disease took over his body, his family watched their precious son retreat, speaking less and losing interactive interest.

Once hospitalized, the boy had an elevated fever of 102.5 and blood tests revealed high numbers of white blood cells, especially [neutrophils](#). When the body is under attack, this unique type of white blood cell helps the body "fight infections and heal injuries." Despite the presence of neutrophils revealing an infection of some kind, brain MRIs, CT and EEG scans, bacterial cultures, and dozens of additional tests came back negative. Nurses and physicians were baffled.

Sterile, hospital odor pervaded the air, and the droll hum of medical monitors drowned in the background. In the center of the room laid the young boy in his mother's comforting and protecting arms. With his head wrapped extensively in white bandages and intravenous tubes and tape covering his arms, physicians noted the involuntary tongue thrusting and uncontrollable arm movements, trying to draw conclusions of what this illness could be ([video](#)).

But the illness continued to progress causing seizures, uncontrolled body movements during sleep and impaired feeding capabilities, requiring the placement of a nasogastric tube to provide food through the nose. Doctors treated the boy with drugs to prevent seizures caused by viral infections, but these did not help.

For 65 days, family and medical professionals watched the mysterious, progressive disorder rack the young toddler's body without any clue to the cause. However, there was one spark of hope.

In 2009, [Susannah Cahalan](#), a young and ambitious reporter in her prime, suffered from hallucinations,

uncontrollable body movements and loss of memory without any clue as to what was the cause. Many exhausted medical professionals diagnosed her with schizophrenia, ready to commit her to the psychiatric ward. But one doctor saved her life with a lucky last minute medical intervention.

Dr. Souhel Najjar, a prominent neurologist, recalled reading a case study in the medical literature about a rare autoimmune disease that affected young college women. All women suffered similar psychiatric symptoms, and they all had tumors in their ovaries and the presence of the NMDA-receptor-seeking anti-bodies in the brain. Even though Cahalan had no discernible tumors, the symptoms were identical. Dr. Najjar ordered additional tests and discovered high levels of anti-bodies to NMDA-receptors in Cahalan's cerebral spinal fluid (CSF), revealing anti-NMDA receptor encephalitis.

[Anti-NMDA receptor encephalitis](#) is a disease where the body's own antibodies, which are created by the body's immune system to defend unwanted external pathogens, attack NMDA receptors in the brain. NMDA receptors are proteins that control electrical impulses in the brain, "critical for functions such as judgment, perception of reality, human interaction, the formation and retrieval of memory, and the control of unconscious activities (like breathing and swallowing)." So in other words, this disease causes one's own body to attack and defend itself, thinking that an external pathogen is causing havoc on the body.

With time running out on the clock, Dr. Najjar decided to administer a trial of [intravenous immunoglobulin \(IVIG\)](#), which replaces the sick patients plasma (a blood component) with plasma of healthy individuals to help the immune system battle the invading disease, "neutralizing and rendering the autoantibodies as harmless." After numerous treatments of IVIG, Cahalan slowly started to regain her mental and physical capabilities, eventually becoming "normal" by medical standards.

Perhaps the doctors in the boy's treatment had heard of Cahalan's case or another case of this disease, and as a last ditch effort they tested his CSF for anti-NMDA-receptor antibodies.

Finally, a test came back positive.

The doctors immediately administered IVIG to counteract the advancing anti-NMDA-R encephalitis.

Clear bags of IVIG hung above the young boy's head, as liquid trickled down into his veins. Remarkably, over a month after the IVIG trial, the uncontrolled lip smacking, tongue thrusting and body movements significantly reduced. After three months, family and medical professionals watched the toddler recover, gaining back the ability to walk and physically eat food without a tube. Slowly but surely, the toddler was returning to his former self. And one year after the onslaught of the disease, the boy was only in speech therapy.

To date, this is the first case recorded of the youngest victim afflicted with anti-NMDA-R encephalitis. With so little known about this crippling autoimmune disease, it is difficult to diagnose. In retrospect, the medical professionals acknowledge the uncontrolled mouth and body movements during sleep were a sign of anti-NMDA-R encephalitis. Early diagnosis is often associated with a tumor, but ["40% of adult patients and 73% of pediatric patients"](#) with this illness have no identifiable tumors. Both Cahalan's and the young boy's physicians chose immediate IVIG trials after finding no tumors and detecting the presence of antibodies to NMDA receptors in the cerebral spinal fluid.

In both scenarios, tireless but dedicated physicians and devoted family members stood by their patients and loved ones to cure this debilitating disease. With so little known about the disease and no discrimination towards its victims, who will be strike next?

**Citations:**

Cahalan, Susannah. *Brain on Fire: My Month of Madness*. New York: Free, 2012. Print.

Hartung, H-P et al. "Clinical Applications of Intravenous Immunoglobulins (IVIg) - beyond Immunodeficiencies and Neurology." *Clinical and Experimental Immunology* 158.Suppl 1 (2009): 23-

33. *PMC*. Web. 12 Sept. 2015.

"Neutrophilic Leukocytosis- Blood Disorders." *Merek Manuals Consumer Version*. Web. 12 Sept. 2015.

"Response to Immunotherapy in a 20-month-old boy with anti-NMDA receptor encephalitis."- *Video*. Web. 13 Sept. 2015.

Vilensky, Joel A., et al. "Response to immunotherapy in a 20-month-old boy with anti-NMDA receptor encephalitis." *Neurology* 76.1 (2011): 105-105.

"What Is Anti-NMDA Receptor Encephalitis?" *The Anti NMDA Receptor Encephalitis Foundation Inc*. Web. 12 Sept. 2015.

Update 9/18/2015: Edited by Paige Jarreau